



**12th Annual Meeting of the
Egon and Ann Diczfalusy Foundation
Scientific Programme and Abstract Book**

11 – 12 May, 2018

Budapest

**Editor in chief:
Gábor Németh**

**Co-editors:
Tamás Bitó, Petru Chitulea, Tihomir Vejnovic**

ISBN: 978-615-00-1550-7

**12th Annual Meeting of the
Egon and Ann Diczfalusy Foundation**

Scientific Programme and Abstract Book

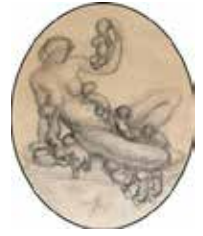11 – 12 May, 2018

Budapest

**Editor in chief:
Gábor Németh**

**Co-editors:
Tamás Bitó, Petru Chitulea, Tihomir Vejnovic**

ISBN: 978-615-00-1550-7



Egon and Ann Diczfalusy Foundation
for
Supporting Research in Reproductive Health

In collaboration with the Medical Faculty, University of Szeged (Hungary), Department of Obstetrics and Gynaecology, University of Szeged, the Reproductive Health-working Group of the Szeged branch of the Hungarian Academy of Sciences and Clinic for Gynecology and Obstetrics, Clinical Centre of Vojvodine (Serbia)

12th Annual Meeting of the
Egon and Ann Diczfalusy Foundation

Scientific Programme and Abstract Book

11 – 12 May, 2018

Publisher: Egon and Ann Diczfalusy Foundation

Address: Semmelweis 1, Szeged, Hungary, 6725

e-mail: bartfai.gyorgy@med.u-szeged.hu

web page: www.diczfalusy.hu

Responsible publisher: Prof. Dr. György Bártfai

Generál Nyomda Kft. Szeged, 2018.

ISBN: 978-615-00-1550-7



Dear Colleagues,

It is a great pleasure to welcome you at the Diczfalusy Scientific Symposium in this Spring. The aim of the “Egon & Ann Diczfalusy Foundation” is to support research in reproductive health and to provide updated knowledge to Obstetricians-Gynaecologists in Central-Eastern Europe.

To foster its aims, every year the Foundation organises an Annual Meeting with a Diczfalusy Award Lecture Symposium (DAL) on Reproductive Health. This year the Diczfalusy Foundation will organise its 12. Annual Meeting, the DAL 12, between 11-12 May, 2018 in Budapest, Hungary. This meeting will have a special significance as we will organize it in first time as part of the ESC 15th

Congress of the European Society of Contraception and Reproductive Health. On behalf of the Scientific Committee and the Presidium of the Foundation, it is our pleasure and privilege to invite you to participate in this event.

We look forward to the pleasure of welcoming you in Budapest and we hope that the excellent scientific programme and the friendly atmosphere of the host city will give you an unforgettable memory on this event!

Yours sincerely,

A handwritten signature in blue ink, which appears to read 'Bártfai György'.

Prof. emeritus Dr. György Bártfai
President of the “Egon & Ann Diczfalusy Foundation”

Congress venue

HungExpo

Albertirsai út 10., Budapest, Hungary, H-1011

Website: hungexpo.hu/en

Scientific Committee

Tamás BITÓ (H)

Nenad CETKOVIC (SRB)

Gheorghe FURAU (RO)

Peter KOLIBA (CZ)

Nicolae SUCIU (RO)

András SZILÁGYI (H)

Aleksandra VEJNOVIC (SRB)

Poster Evaluation Committee

Marius CRAINA (RO) *President*

Nenad CETKOVIC (SRB)

Erich COSMI (I)

Nicolae SUCIU (RO)

András SZILÁGYI (H)

The founder's rights are fully assigned to:

Gyula TELEGDY

Szeged, Hungary

The Board of Trustees

Giuseppe BENAGIANO

Honorary President

Rome, Italy

György BÁRTFAI

President

Szeged, Hungary

Henry L. GABELNICK

Vice-President

Arlington, VA, USA

Tihomir VEJNOVIC

Vice-President

Novi Sad, Serbia

Members of the Board

David ARCHER

Norfolk, VA, USA

Peter KOLIBA

Vresina, Czech Republic

Ferenc BARI

Szeged, Hungary

Britt-Marie LANDGREN

Stockholm, Sweden

Dieter BETTELHEIM

Vienna, Austria

Ana MITROVIC JOVANOVIC

Belgrade, Serbia

Petru CHITULEA

Oradea, Romania

Gábor NÉMETH

Szeged, Hungary

Erich COSMI

Padua, Italy

Zuzana NIZNANSKA

Bratislava, Slovakia

Ilpo HUHTANIEMI

London, UK

György THALER

Budapest, Hungary

Secretary

Cristian FURAU

Arad, Romania

Young Diczfalusy Group

Aleksandra VEJNOVIC

Novi Sad, Serbia

Cristian FURAU

Arad, Romania

Gyula Richárd NAGY

Budapest, Hungary

Financial Committee

János ANNUS

Chairman of the Committee

Invited speakers and chairs

David ARCHER (USA)

Ilpo HUHTANIEMI (UK)

Ferenc BARI (H)

József Gábor JOÓ (HU)

György BÁRTEFAI (H)

Ana MITROVIC JOVANOVIC (SRB)

Giuseppe BENAGIANO (I)

Peter KOLIBA (CZ)

Dieter BETTELHEIM (A)

Gyula Richárd NAGY (H)

József BÓDIS (H)

Gábor NÉMETH (H)

Nenad CETKOVIC (SRB)

Zuzana NIZNANSKA (SK)

Petru CHITULEA (RO)

Aleksandar STEFANOVIC (SRB)

Erich COSMI (I)

Nicolea SUCIU (RO)

Marius CRAINA (RO)

András SZILÁGYI (H)

Michael FEICHTINGER (A)

Gyula TELEGDY (H)

Cristian FURAU (RO)

Aleksandra VEJNOVIC (SRB)

Gheorghe FURAU (RO)

Tihomir VEJNOVIC (SRB)

Congress Office:

ESC Central Office

Tel: +32 2 582 0852

Fax: +32 2 582 5515

info@escrh.eu

www.escrh.eu

Sponsor for the Foundation:

Richter Gedeon Plc.

Friday, 11 May, 2018, 12:00 – 13:30

Board Meeting – Working Lunch for Board members

Expo Congress Hotel, Congress Room (1st floor)

12th Annual Meeting of the „Egon and Ann Diczfalusy Foundation”

Scientific program

Room D, Friday – 11 May 2018

- 17:00 – 18:30** **Opening ceremony**
- 17:00 – 17:05** **Presidium**
Gyula Telegdy (Hungary)
Nicolae Suciu (Romania)
Tihomir Vejnovic (Serbia)
József Bódis (Hungary)
György Bártfai (Hungary)
- 17:05 – 17:30** **Bestowal ceremony**
- 17:05 – 17:10** **„Young Scientist Award”**
Laudation by Aleksandra Vejnovic (Serbia)
- 17:10 – 17:25** **Acceptance speech by Michael Feichtinger (Austria)**
**The future of reproductive medicine - towards minimal
invasive techniques and personalized ART**
- 17:25 – 17:30** **Hand over the Medal by György Bártfai (Hungary)**
- 17.30 – 18: 00** **Keynote lecture**
Chair: Gábor Németh (Hungary)
Contraception in adolescence
Giuseppe Benagiano (Italy)
- 18:00 – 18:30** **Session 1**
Chair: Gyula Richárd Nagy (Hungary),
Peter Koliba (Czech Republic)
Marius Craina (Romania)
- 18:00 – 18:15** **Arterial and kidney remodelling in preterm growth restricted
fetus and newborn**
Erich Cosmi (Italy)
- 18:15 – 18:30** **Report of the Young Diczfalusy Fellows**
Aleksandra Vejnovic (Serbia)

12th Annual Meeting of the „Egon and Ann Diczfalusy Foundation”

Scientific program

Room C, Saturday – 12 May 2018

- 8:15 – 9:45** **Session 2**
Chair: Petru Chitulea (Romania), Gheorghe Furau (Romania), Aleksandar Stefanovic (Serbia)
- 8:15 – 8:35** **Challenges and solutions in gradual medical education**
Ferenc Bari (Hungary)
- 8:35 – 8:55** **“Driving licence” for the delivery ward – how to become a good obstetrician**
Dieter Bettelheim (Austria)
- 8:55 – 9:10** **Paradigm shift in the practical education of gynaecology**
József Bódis, József Gábor Joó (Hungary)
- 9:10 – 9:25** **The resident’s view on the current practical education and the vision of the future**
Cristian Furau (Romania)
- 9:25 – 9:30** **Four-year efficacy and safety of the Levosert levonorgestrel intrauterine system**
Mitchell D. Creinin (USA)
- 9:30 – 9:45** **Discussion**
- 9:45 – 10:00** **Intermission**
- 10:00 – 11:30** **Session 3**
Chair: Zuzana Niznaska (Slovakia), András Szilágyi (Hungary), Nenad Cetkovic (Serbia)
- 10:15 – 10:35** **Non-Peptide Gonadotropin Releasing Hormone Antagonist for Treatment of Heavy Menstrual Bleeding in Women with Uterine Myomas**
David Archer (USA)
- 10:35 - 10:55** **Spermatogenesis without testosterone**
Ilpo Huhtaniemi (UK)
- 10:55 - 11:15** **Ovarian Ageing**
Ana Mitrovic Jovanovic (Serbia)

| | |
|----------------------|--|
| 11:15 – 11:35 | Current trends in the diagnostic and operative laparoscopy Gábor Németh (Hungary) |
| 11:35 – 11:45 | Discussion |
| 11:45 – 12:00 | Poster session Chair: Marius Craina (Romania), András Szilágyi (Hungary), Aleksandar Stefanovic (Serbia) (Presentation of the best posters) |
| 12:00 – 12:10 | Closing Remarks Giuseppe Benagiano (Italy), Tihomir Vejnovic (Serbia) |

Young Scientist Prize

The Prize is given annually to an internationally acknowledged young investigator, for his/her achievements in improving Reproductive Health.

One side depicts a mother with her child and Professor Diczfalusy's Life-Motto: **Empathy, Science and Hope**

The other side shows the Dom square with the Votive Church and the Microbiological Institute of the University, Szeged and a frequently quoted phrase from him: **Medicina, Anchora, Salutis.**



The previous years' awarded were:

For The Young Scientist Award

- 2007 Dr. Nathalia Maria Cruz (Sweden)
- 2008 Dr. Eszter Ducza (Hungary)
- 2009 Dr. Claudio Avram (Romania)
- 2010 Signe Altmae, Ph.D. (Sweden)
- 2011 Dr. Cristian Furau (Romania)
- 2011 Dr. Dunja Lonchar (Serbia)
- 2012 Dr. Attila Molvarec (Hungary)
- 2013 Dr. Silvia Visentin (Italy)
- 2014 Dr. Salvatore Gizzo (Italy)
- 2015 Dr. Gyula Richárd Nagy (Hungary)
- 2016 Dr. Nicolea Bacalbasa (Romania)
- 2017 Dr. Aleksandra Vejnovic (Serbia)

The Diczfalusy Prize

The prize acknowledges one's lifetime scientific achievements in the field of research on Reproductive Health with a miniature version of the original statue of Klara Tobias, called the „Hungarian Pieta 1956”.

For The Lifetime Scientific Achievement Award

- 2007 Prof. Salvatore Mancuso (Italy)
- 2008 Prof. Britt-Marie Landgren (Sweden)
- 2009 Prof. Mahmud Fathalla (Egypt)
- 2010 Prof. David Archer (USA)
- 2011 Prof. Biran Affandi (Indonesia)
- 2012 Prof. Badri Saxena (India)
- 2013 Prof. Mark Bygdeman (Sweden)
- 2014 Prof. Ilpo Huhtaniemi (Finland)
- 2015 Prof. Gyula Telegdy (HU)
- 2016 Prof. Giuseppe Benagiano (Italy)
- 2016. Erik Bogsch (Hungary)
- 2017 Prof. Marius Craina (Romania)



**12th Annual Meeting of the
Egon and Ann Diczfalusy Foundation**

*Laudation and Abstracts of Lectures
in order of appearance*

Young Scientist Award

Laudation of Dr. Michael Feichtinger

Aleksandra Vejnovic, MD

Clinic of Gynecology and Obstetrics, Clinical Center of Vojvodina, Faculty of Medicine, University of Novi Sad, Novi Sad, Serbia

The Young Scientist Award is high recognition given to Young Diczfalussy Fellows for their significant scientific activity and commitment to the Foundation. Moreover, this award represents sign of support of intellectual potential of young Diczfalussy member and scientific achievements that he/she will make in the future.

I have pleasant task to pay tribute to one such a talent, Dr. Michael Feichtinger.

Dr. Michael Feichtinger was born in Vienna and raised in the suburbs of Vienna, Austria. From an early age he was interested in natural sciences. He finished twelve years of elementary and high school and enrolled human medical studies at the Medical University of Vienna, where he studied for six years. Two month-long internships in hospitals in Umeå, Sweden and Perm, Russia, enriched his clinical experience. Another important experience he gained during a year spent at the Karolinska Institute, Stockholm as an Erasmus student, where he collaborated with Kenny Rodriguez-Wallberg. Michael invested time to learn some organizational skills during one year studying health care management at the Danube University in Krems. He also studied Biology for two years.

In July 2012 he graduated from Medical University of Vienna - Department of Medical Genetics, with thesis: *Oct4 expression in amniotic fluid stem cells*.

In August 2017 he became PhD on Clinical Endocrinology at the Medical University of Vienna. His thesis was: *Novel Treatment Approaches to Enhance Fertility Potential in Infertile Women*.

In November same year he finished residency in Obstetrics and Gynecology by passing specialist exam in Jena, Germany. On his own initiative he spread his knowledge and skills attending different courses:

- Masterclass in Vacuum Assisted Delivery; Vacca Research, 2013
- Statistics for Medical Professionals, Stanford School of Medicine 2015
- Writing in the Sciences, Stanford School of Medicine 2015
- Colposcopy diploma AG-CPC 2016
- Ultrasound Certification ÖGUMI
- Principles of Fertility Preservation for Reproductive Health Providers Certificate Course, American Society of Reproductive Medicine 2017

From 2005-2018 he worked as scientific assistant at the Wunschbaby Institut Feichtinger (www.wunschbaby.at) focusing on reproductive medicine, where nowadays he works as a consultant.

Currently he attends post-doctoral studies at the Karolinska Institute, Department of Oncology/Pathology. He is involved in regular teaching activity at the Medical University of Vienna and the University of Applied Sciences in Vienna. Michael is Young Ambassador of ESHRE (European Society of Human Reproduction and Embryology).

Besides, from his students days he is active in science. He participated in several national and international conferences, won scientific research fellowship at the reproductive unit of Karolinska University Hospital in Stockholm in 2016, and regularly publishes scientific papers of which last in January 2018.

His persistence and diligence was also recognized by others when he won different grants and scholarships:

- Visiting scholarship for the European Forum Alpbach in 2009,
- ERASMUS scholarship 2011/12,
- Top-Stipendium of the Niederösterreich Region 2011,
- Scientific Grant of the Mayor of the City of Vienna 2014;
- Young Ambassador of the European Society of Human Reproduction and Endocrinology (ESHRE) 2016;
- Ferring research price at the annual meeting of the Austrian society of reproductive medicine in Eisenstadt, October 2016,
- Veronika Fialka-Moser Diversity Price for Research, November 2017

However, not only science fills the days of Michael Feichtinger. He enjoys singing, playing trombone and guitar. He speaks German, English, Italian, Swedish and Russian language. His curiosity, creativity and respect for the people and nature makes this year's winner worthy of Young Scientist Award and this laudation. Congratulations!

Young Scientist Award

Acceptance speech by Michael Feichtinger (Austria)



The future of reproductive medicine - towards minimal invasive techniques and personalized ART

Within the last 40 years, assisted reproductive technologies (ART) have become widely applied worldwide. However, success rates remain relatively low and many aspects of human reproduction are not yet discovered. While various fields in medicine are developing towards a personalized approach, many IVF clinics are still applying a “one size fits all” strategy. Indeed, several adjuvant therapies in ART have been proven inefficient and expensive.

With the dawn of personalized medicine and more affordable genetic testing, a new frontier opens for reproductive medicine offering a wide range of possibilities. The goal of reproductive medicine physicians should be however, to perform as minimal invasive procedures as possible when dealing with the embryo. Polar body analysis for example may be a feasible technique to rule out maternal age related aneuploidies without affecting embryonic development. Another promising, non-invasive approach to diagnose embryonic viability might be preimplantation genetic testing from culture media as recently described by our group. However, also parental NGS testing might open new treatment strategies and information regarding the underlying cause of infertility. Furthermore, parental carrier screening could identify the risk for monogenetic diseases and allow the selection of healthy embryos. Similarly, in young women, genetic testing could identify the risk for premature ovarian failure and associated conditions and allow for oocyte freezing in young, fertile years. Moreover, through detailed pre-therapeutic parental testing, individualized stimulation approaches might reduce the risk of hyperstimulation and poor ovarian response.

Through these technologies, a more targeted and patient-friendly treatment approach could evolve and help patients to start their own desired family.

Keynote lecture

Hormonal contraception in adolescence

Giuseppe Benagiano

Department of Gynecology, Obstetrics and Urology, Sapienza, University of Rome, Rome, Italy

After some sixty years of ever increasing utilization, hormonal contraception (HC) has made a major impact in the lives of women worldwide, although Family-Planning has taken today a different meaning in Industrialized and in Developing Countries, the reason being that in the former fertility is almost always at, or below, replacement level, whereas in the latter – with the notable exception of China – it is still well above it.

Today, HC takes many forms: combined oral contraceptives (COC), long-acting, injectable progestin-only preparations, the so-called progestin-only “minipill”, progestin-releasing subcutaneous implants or intrauterine devices.

COC have evolved both in terms of route of administration (oral, transdermal, vaginal) and of composition, with 4 generations of progestins having been used and now also natural estrogens. The goal is to offer women the type of method that suits best their needs: adapting technology to individual requirements is the new frontier of family-planning and ensures its highest effectiveness. In this respect, proper counseling can substantially lower the proportion of unintended pregnancies, especially with COC.

In Western Countries, where every method is easily available, specific care can, and therefore must be applied during the various phases of a woman’s life, from adolescence to menopause. In this respect, adolescent often have an irregular lifestyle, difficulties in assessing risk of unintended pregnancy and consequently run a high risk of contraceptive failure and unintended pregnancies. At the same time, a greater awareness is developing among adolescent and young

adult women of the need to prevent unwanted pregnancies. For instance, it has been shown that women complaining of depression had significantly lower probability of having chosen an effective method of contraception.

For decades, long-acting methods of contraception (whether hormonal or not) have been considered all but contraindicated for adolescents, for fear that they may interfere with the maturation of the hypothalamic-pituitary-ovarian axis and even cause infertility. Today, on the other hand, in view of difficulty in compliance with oral contraception by young people, these methods should be offered because of their much better practical effectiveness.

Indeed, in the USA it seems that after proper counselling 2/3 of adolescents will choose a long-acting method. Nonetheless, COCs remain an option, especially when their therapeutic effect may be exploited (see e.g. in cases with hyperandrogenism, dysmenorrhea or premenstrual tension).

In addition, a recent, large epidemiological study demonstrated that the risk of great obstetrical syndromes (GOS) including preeclampsia, fetal growth restriction and preterm delivery, is significantly elevated in the 13 to 15-year old adolescent and decreases with aging. This means that the maturation of the uterus for reproduction may require cyclic menstruations during early adolescence and, in this respect menstruation is widely viewed as serving no purpose other than to reinitiate the endometrial cycle in the absence of pregnancy. Yet, spontaneous decidualization followed by menstrual shedding is confined to a few species, including humans, where placenta formation involves deep trophoblast invasion with remodeling of the spiral arteries in the endometrium and inner myometrium. Defective deep placentation has been associated with the occurrence of GOS. For this reason, a period of cyclic menstruations has been proposed to avoid the risk of GOS in adolescents with polycystic ovary syndrome (PCOS). That is why, it is not considered appropriate to administer hormonal contraception until at least 1-2 years after menarche, and then to prescribe a COC containing a low dose of EE or a natural estrogen in order to minimize interferences with the development of secondary sexual characteristics.

Another issue refers to the possibility that the use of progestin-only oral pills, or progestin long-acting reversible contraception (pLARC) in young adolescents affects the risk of abnormal uterine bleeding, as well as the risk of GOS in case of early pregnancy. Abnormal uterine bleeding accompanying pLARC accounts for most discontinuations of these safe and highly effective agents, thereby contributing to unwanted pregnancies and abortions. The endometrium of pLARC users displays progestin inhibition or defective perivascular decidualization in spiral arteries leading to distended fragile vessels prone to bleeding. Therefore, the fundamental issue of whether the use of progestin-only contraception interferes with the natural process of menstruation preconditioning decreasing the risk of GOS remains to be addressed by appropriate investigations.

In Conclusion, today, HC plays an ever-increasing role in family-planning especially after the successful introduction of highly effective long-acting methods. These can be used by women of all ages and in the foreseeable future their role is bound to increase.

Arterial and kidney remodelling in preterm growth restricted fetus and newborn Silvia Visentin¹, Stefania Vedovato², Monica Maria Mion³, Ambrogio P Londero⁴, Daniele Trevisanuto¹, Martina Zaninotto³, Mario Plebani³, Erich Cosmi¹

¹ Department of Woman and Child Health, University of Padua, Padua, Italy

² NICU, San Bortolo Hospital of Vicenza, Vicenza, Italy

³ Laboratory Medicine, University of Padua, Padua, Italy

⁴ Unit of Obstetrics and Gynecology, S. Polo Hospital, Monfalcone, Italy

Objective: To evaluate cardiovascular function and structure by intima media thickness (IMT) in ascending and abdominal aorta in intrauterine growth restricted (IUGR) and appropriate for gestational age (AGA) fetuses, and to investigate the relationship between vascular damage and kidney dysfunction in IUGR newborn.

Methods: This was a case-controlled study. Singleton pregnancies affected by IUGR with fetal Doppler alterations and controls were included. Ultrasound examinations (fetal biometry, fetal Doppler, fetal aorta intima media thickness (aIMT) in ascending (Asc) and abdominal segment (Abdom), fetal kidney volumes and maternal Doppler) and clinical data were collected. A sample of neonatal urine was taken at 0-2 days after birth.

Results: Twenty-five patients with IUGR and 25 AGA were enrolled. All IUGR fetuses presented arterial Doppler alterations. At growth scan (median week 31) Asc and Abdom aIMT were significantly different between IUGR and AGA group (Abdom 1.28 vs 0.6 mm, Asc 0.95 vs 0.5 mm, $p < 0.0001$), both correlating with aorta Doppler PI, in the isthmus and abdominal part ($p < 0.0001$), respectively. Proteinuria, albuminuria, proteinuria/creatinuria, albuminuria/creatinuria ratio (ACR) and natremia were significantly higher in IUGR newborns than AGA. There was a negative correlation in IUGR neonates between kidney's volume and ACR (r^2 0.72, p 0.0004).

Conclusions: IUGR condition induces in preterm IUGR fetuses and newborns an arterial remodeling and renal impairment that could explain the increased predisposition to cardiovascular disease in adult life and highlights the importance of early identification and intervention in pediatric risk factors for cardiovascular disease.

Key words: IUGR, intima media thickness, kidney, fetus, newborn

The authors declared no conflict of interest and the absence of any source of financial support of the study

Author for correspondence (and reprint requests):

Erich Cosmi, MD, PhD

Director of Maternal and Fetal Medicine Unit

Associate Professor of Obstetrics and Gynecology

University of Padua School of Medicine, Padua, Italy

Via Giustiniani No 3, 35128, Padua, Italy

Tel. +39-339-8146745; Fax +39-049-8211842

E-mail: ecosmi@hotmail.com

Report of the Young Diczfalusy Fellows

Aleksandra Vejnovic (Serbia)

Abstract had not arrived

Challenges and solutions in gradual medical education

Ferenc Bari

Department of Medical Physics and Informatics, Faculty of Medicine, University of Szeged, Szeged, Hungary

Although medical (health profession) education has always required continuous changes the exponential growth of general and specific knowledge urges more complex and faster modification of the curriculum on both gradual and post-gradual level. The major limiting factors of the education are the restricted time-frame, the high cost of the training and the boundaries of single human capacities. Since there are medical schools of various sizes, training concepts and resources the concepts and solutions how to deal with challenges are different, there are only few successful attempts even in country levels to harmonize education programs. The external factors (e.g.: ageing population, chronic disease prevention and management, human genome program and personalized medicine, information science etc.) represent a similar –although with various driving force-frame everywhere there are few coordinated strategies to adapt to change. It is well-known and accepted fact that most of the factual knowledge is available on the internet therefore the educators' tasks change from providing to highlight the required fundamental knowledge. Since the ultimate goal of the training is to prepare students for life-long learning an additional fundamental aspect is the assessment of the knowledge. Effective teaching methods involve ways of testing the progression in learning at both individual and group levels. Major efforts are put on small group trainings where students learn how to share tasks and experiences, how to interpret and discuss about specific cases or problems. Effective medical education involves more and more skill training in specialized and well-equipped laboratories. Almost all kind of medical procedures could be studied even repeatedly in artificial and controlled circumstances. Simulation training complements and does not replace patient-doctor interactions. The obvious third pillar of effective education is the successful communication at all levels of the medical profession. Communication within the professional groups (doctors, nurses, physical therapists, pharmacologists etc.), with patients and relatives but even with the entire society through the media require training and appropriate skills and attitudes. The various levels of medical education should be handled as an entity and the core concepts for each level need to be clearly defined. It should also be accepted that medical education has become a specific science with methodology and literature. The faculty development should also contain a goal oriented training of teachers. Without using the results of medical education science there is no way for an effective overcome the challenges.

Keywords: continuing medical education, skill training, effective communication, information technology

“Driving license” for the delivery ward – how to become a good obstetrician

Dieter Bettelheim

Department of Obstetrics and Gynecology, Medical University Vienna, Vienna, Austria

At first view it seems to be a little bit strange if you mix up two different scenarios. A driving license which allows everybody to drive a car, a bus or a motorcycle in normal road traffic and on the other hand the very complex situation of appropriate decision making and skillful acting in the delivery room. How to find an appropriate name for a tool which produces evidence for someone who is experienced and well trained being able to take over responsibility in the delivery room and in obstetrical wards? Actually it is totally unclear if one examination is enough to allow autonomous working in the intensive care unit of a delivery room.

After a short historical introduction I will try to give an overview about different obstetrical demands caused by the change of woman’s role in the society and also caused by the change of interaction between doctors and their patients.

Medical background and knowledge are of the same importance as spatial sense and technical skills.

The ability of finding the right way to communicate is highly demanded being able to interact with a woman in a vulnerable period of her life.

A good obstetrician has to take the role of a counselor and confidante to some of his patients. Because of the fact that many patients expect you to perform the delivery by yourself and babies arrive at all times obstetricians have to be aware of the fact that they have irregular working hours in addition to the employment in a hospital or in the private office.

Paradigm shift in the practical education of gynecology

József Bódis¹, József Gábor Joó²

¹ Department of Obstetrics and Gynecology, University of Pécs, Pécs, Hungary

² 1st Department of Obstetrics and Gynecology, Semmelweis University, Budapest, Hungary

Postgraduate education, particularly in surgical specialties has been based on the apprenticeship system.

In Hungary the education of gynecologists was organized in a simple system for decades. Each colleague has spent the postgradual education in one hospital, where only certain areas of OB/GYN were available. Due to this system, the majority of the young gynecologists had been having no opportunity to achieve competency in the whole obstetrics and gynecology.

Nowadays the education system is available only accredited hospitals and departments, where all competencies in OB/GYN can be acquired.

Among these main competencies cesarean section, operative vaginal delivery, perineal repair, manual removal of placenta, evacuation of the uterus and diagnostic laparoscopy are the most important ones.

In Hungary to fulfill the criterions the young colleagues have to perform 20 cesarean sections, 100 per vias naturales deliveries, 20 manual removal of the placenta, 20 evacuation of the uterus and 10 diagnostic laparoscopies. Out of these basic interventions urology, anesthesiology, surgery, oncology, endocrinology and emergency medicine are also of high importance; the residents have to spend several months at each division.

Assessment of technical competencies involves the use of a criterion, with which the individual's skill can be compared with the absolute standard. It must be highlighted that training and assessment are complementary.

There can be no doubt, that the competency-based education of gynecologists is inevitable in maintaining the public confidence in medical profession. One of the greatest challenges of the education system is to develop the tools of training to improve continuously the skill and knowledge of the young OB/GYN specialists.

It is a great responsibility of the leaders in OB/GYN and in the health care system of Hungary to ensure that the obstetric and gynecology workforce of the future will be competent to perform the tasks expected. It demands the necessary tools and the complementary assessment system which can guarantee and effective education of high quality.

The resident's view on the current practical education and the vision of the future

Cristian Furau, Gheorghe Furau

“Vasile Goldis” Western University of Arad, Arad, Romania

The evolution of medicine and of the school of medicine was tremendous especially in the last century and nowadays. The amount of new information that is constantly added to the medical knowledge determined the evolution of the teaching process, from the hypocratic apprenticeship to nowadays ultraspecialized programs.

In my lecture I will explore today's current practical education of the residents highlighting the specialty obstetrics and gynecology. Among the key aspects presented, I will focus on: delivering theoretical and practical knowledge and their relevance, developing practical skills, using hands-on- training courses, the challenges for both mentor and apprentice, ethical aspects.

In the last part of the presentation, I will offer my vision for the future. For that I will further develop the possible evolution of the mentor-apprentice relation to an equal-partner relation.

Non-Peptide Gonadotropin Releasing Hormone Antagonist for Treatment of Heavy Menstrual Bleeding in Women with Uterine Myomas [1]

David F. Archer

Department of Obstetrics and Gynecology, Eastern Virginia Medical School, Norfolk, Virginia, USA

Background: Uterine myomas are common benign tumors in women. Thirty per cent of women with uterine myomas report heavy menstrual bleeding as a significant problem. These women are often anemic and require iron therapy. Heavy menstrual bleeding is associated

with endometriosis, anovulation, and adenomyosis and in some instance no obvious cause (idiopathic) is identified.

Clinical management involves the use of combination oral hormonal contraceptives, levonorgestrel releasing intrauterine devices, Tranexamic acid (anti-fibrinolytic), and peptide gonadotropin releasing hormone agonist with add back hormonal therapy. Non-steroidal anti-inflammatory drugs do not appear to reduce the blood loss in women with myomas.

Materials and Methods: A multicenter clinical study was carried out in women between the ages of 18 to 50 with heavy menstrual bleeding. Assessment of blood loss used the alkaline hematinic method on collected sanitary products. A blood loss of >80 mL per menstrual period was considered heavy menstrual bleeding. Uterine myoma volume and number was documented using transvaginal ultrasound. Elagolix a non-peptide oral gonadotropin releasing agonist administered in various daily doses was compared to placebo. The outcomes were a reduction in menstrual blood loss of >50% of the baseline values and the percent of women who normalized their blood loss <80 mL per menstrual period along with uterine volume.

Results: 271 women were randomized; 221 received active treatment (160 women received Elagolix alone; 61 women received Elagolix and an add-back therapy) and 50 received placebo. The mean MBL at baseline was 267 mL; the mean largest fibroid volume was 90 cm³. The percentage of women with documented reduction in MBL to <80 mL and ≥50% from baseline (74%–97% in Elagolix-treated groups vs. 13%–33% in placebo groups $p<0.001$). Elagolix plus add-back therapy regimens also numerically reduced the percentage of moderate to very heavy bleeding days compared with baseline, but increased the percentage of spotting days compared to Elagolix alone. Most Elagolix dosing regimens had statistically significantly greater reductions in the mean percentage change in uterine volume compared with placebo. The co-administration of add-back therapies generally resulted in smaller reductions in fibroid and uterine volumes relative to administration of Elagolix alone.

Discussion: Elagolix an oral non-peptide gonadotropin receptor antagonist decreased measured menstrual blood loss in a dose dependent manner. The addition of add back therapy (estrogen plus progestogen) did not significantly affect the improvement in measured menstrual blood loss compared to Elagolix alone. Uterine volume decrease was different from placebo and not affected by the addition of add back therapy.

1. Archer, D.F., et al., *Elagolix for the management of heavy menstrual bleeding associated with uterine fibroids: results from a phase 2a proof-of-concept study*. Fertil Steril, 2017.

Spermatogenesis without testosterone

Ilpo Huhtaniemi

**Institute of Reproductive and Developmental Biology, Department of Surgery & Cancer,
Imperial College London, London W12 0NN, UK**

The two pituitary gonadotrophins, luteinising hormone (LH) and follicle-stimulating hormone (FSH), and in particular LH-stimulated high intratesticular testosterone (T) concentration, are considered crucial for spermatogenesis. We have revisited these concepts in genetically modified mice, one being the *LH receptor (R)* knockout mouse (LuRKO), the other a transgenic mouse expressing in Sertoli cells a highly constitutively activating *Fshr* mutation (Fshr-CAM). It was found that full spermatogenesis was induced by exogenous T treatment in LuRKO mice at doses that restored intratesticular (IT) T concentration to a level corresponding to normal circulating T levels in wild-type mice, i.e. only 2-3% of the normal high ITT concentration. When LuRKO and Fshr-CAM mice were crossed, the double mutant mice with strong FSH signaling but minimal T levels showed near-normal spermatogenesis, even when their residual androgen action was blocked with the strong antiandrogen flutamide. Our findings challenge two dogmas of the hormonal regulation of male fertility: (1) high intratesticular concentration of T is not necessary for spermatogenesis, and (2) strong FSH stimulation can maintain spermatogenesis without T. These findings have relevance for the development of hormonal male contraception and for the treatment of idiopathic oligozoospermia.

Ovarian aging and oxydative stress

Ana Mitrovic Jovanovic

Univesity Clinic for GYN and OB, Narodni front Schoole of Medicine, Belgrade, Serbia

Human aging is developed of accumulation of physical, environmental and social factors.

Aging – Physiological process or disease?!

Various factors with aging, as changes of metabolic control, gene expression and production of high levels of reactive oxygen species (ROS) could cause DNA damage accumulation, abnormal oncogenes activities, metabolic alteration and excessive ROS generation. These mechanisms cause cell proliferating arrest and generate features as constitutive production of high ROS levels critical for the senescent phenotype maintenance. The inefficient electron transfer in mitochondrial respiratory chain is believed to be a main ROS source among diverse possible enzymatic and nonenzymatic sources. A fine balance between oxidant and antioxidant mechanisms leads to continuous modulation of ROS production, location and inactivation in both physiological and pathological conditions. Endogenous antioxidants like the enzymes of catalase family, glutathione group, thioredox related group and superoxide dismutase together with exogenous antioxidant as reduced glutathione, carotenoids and vitamins C and E, constitute the indispensable ROS detoxifying system.

Antioxidant capacity in female follicular fluid correlates with outcome and decreases with age. Antioxidant capacity in semen correlates with sperm quality and decreases with age. Increased male age is associated with increased DNA fragmentation and reduced IVF success. Follicular fluid reactive oxygen species correlate negatively and total antioxidant capacity correlated

positively with clinical pregnancy rate. ROS induce granulosa cell apoptosis. Apoptosis also was increased in older women.

Advanced glycation end –products (AGEs) are toxic end-products that accumulate with age due to increased circulating glucose and/or cooking of foods at high heat. AGEs induce oxidative stress. Elevated levels in serum and follicular fluid were associated with a reduced chance of pregnancy. High levels also correlated with a reduced ovarian response.

Natural ovarian aging, an abnormal ovarian reserve test (AFC <5-7 or AMH <0,5-1,1 ng/ml) advanced maternal age (>40) or any other risk artificial factor for poor ovarian response is based on pathophysiology of reduced FSH receptor expression, lower intra-ovarian testosterone levels and deficiency in systemic IGF-1 levels .

Alternative strategies to manage poor responders is increasing follicle sensitivity to FSH with testosterone, DHEA, dexamethasone and growth hormone (GH). GH stimulates granulosa cell proliferation and ovarian response to FSH through IGF-1 synthesis. Higher intrafollicular GH levels have been correlated with oocyte and embryo competence. Poor responders have low IGF-1 levels.

Poor nutrition and the increase of oxidative stress and advanced glycation end –products with age appear to play a much larger role in both partners on fertility therapy and IVF cycles outcome than previously appreciated. Nutritional supplements may play an important role in the preparation of infertile couples for IVF, particularly those who are older.

Exercise, weight loss, a more nutritious diet and supplements all enhance erectile function without the need for drugs.

Current trends in diagnostic and operative laparoscopy

Gábor Németh

Department of Obstetrics and Gynaecology, University of Szeged, Szeged, Hungary

Gynecologic laparoscopy has developed from a limited surgical procedure used only for diagnosis to a major surgical tool used to treat a numerous of gynecologic disorders. Today, laparoscopy is one of the most common surgical procedures performed by gynecologists.

Laparoscopy continues to evolve as more sophisticated instrumentation allows a greater variety of procedures to be performed. In the past, many of these procedures would have been limited to laparotomy and would have required a prolonged recovery period. Some procedures, such as tubal ligation, ectopic pregnancy removal, and simple adhesion managing, appear to be safely and efficiently performed laparoscopically. In the last decades laparoscopy become the first intervention to be chosen in the case of managing ovarian cysts, adnexal mass, supravaginal amputation of the uterus. The total removal of the uterus also can be performed by laparoscopy. In the other hand diagnostic laparoscopy is became the “gold standard” in the diagnosis and treatment of infertility.

The laparoscopic approach for potential gynecologic malignancies remains controversial. In cases of ovarian masses with low risk of malignancy, laparoscopy has become the approach of choice. In questionable cases, preliminary steps should be taken to stage the patient, including obtaining pelvic washings, inspecting the entire peritoneal cavity and pelvic structures, and biopsy of suspicious lesions. Frozen section pathological evaluation can be obtained intraoperatively to diagnose or exclude malignancy.

In the case where a malignancy is unexpectedly diagnosed during laparoscopy, concern remains that spilling the contents of an ovarian malignancy into the abdominal cavity during removal might worsen the long-term prognosis. However, the patient’s prognosis does not appear to be worsened as long as definitive treatment is not delayed and is carried out either immediately or within a matter of days. The usefulness of robotics in laparoscopic surgery continues to be determined. The first FDA-approved robotic surgical device called AESOP (Automatic Endoscopic System for Optimal Positioning, Computer Motion, Inc, Santa Barbara, Calif) was introduced in 1994. This system allowed the surgeon to control the orientation of the laparoscope through voice commands.

**12th Annual Meeting of the
Egon and Ann Diczfalusy Foundation**

Abstracts of Posters

Four-year efficacy and safety of the Levosert® levonorgestrel intrauterine system

Mitchell D. Creinin, MD

Department of Family Planning, Department of Obstetrics and Gynecology,

University of California, Davis; Sacramento, USA

Objective: Evaluate four-year efficacy and safety data for Levosert®, a levonorgestrel 52 mg contraceptive intrauterine system (IUS) currently approved for contraception for up to three years, based on an ongoing multicenter trial evaluating the product for up to ten years of use.

Design and Methods: Eligible nulliparous and multiparous women aged 16-45 years were enrolled and followed in the clinical trial. Women aged 36-45 years received the IUS for safety evaluation only. Scheduled study visits occurred four times in the first year and every six months thereafter. Participants completed a daily diary to indicate other contraceptive use and we excluded cycles from the analysis in which another contraceptive method was used. We assessed pregnancy rates (by Pearl Index and life-table analysis) based on the first 48 months of subject participation and safety outcomes obtained for all data regardless of duration of exposure through the cutoff date for this analysis.

Results: Successful IUS placement occurred in 1,568 (98%) women aged 16-35 years and 146 (97%) women aged 36-45 years, of whom 1,011 (57.7%) were nulliparous and 438 (25.1%) were obese. Among women 16-35 years at enrollment, eight pregnancies occurred with three in nulliparous women and one in an obese woman. One pregnancy occurred following perforation and one following expulsion. Six (75%) of the eight pregnancies were ectopic. The Pearl Index for year one was 0.15 (95% CI 0.02-0.55) and year four was 0.20 (95% CI 0.01-1.13). The cumulative Pearl Index through 4 years was 0.21 (95% CI 0.09-0.41). Cumulative life-table pregnancy rates through years two, three and four were 0.50 (95% CI 0.22-1.11), 0.61 (95% CI 0.29-1.28) and 0.83 (95% CI 0.39-1.76), respectively. Perforation following IUS placement occurred in two (0.1%) women; both were diagnosed within the first year. Expulsion was reported in 63 (3.7%) participants, most (50 [79.4%]) during the first year of use. Pelvic infection was diagnosed in 12 (0.7%) women. Amenorrhea developed in approximately 19% of users by the end of the first year of use, in 27% by the end of the second year of use, in 37% by the end of the third year of use, 41% by the end of the fourth year of use. Only 38 (2.2%) women discontinued due to bleeding complaints.

Conclusions: Levosert® is highly effective and safe over four years of use in nulliparous and parous women as well as non-obese and obese women. Most expulsions and discontinuation for bleeding occur during the first year of use.

Keywords: Contraception, Intrauterine system, Levonorgestrel, Levosert®

References:

1. Thomas M. *Obstet Gynecol* 2017;129 (5, Suppl): 115–16 [Abstract 11A]
2. Gedeon Richter. Levosert SmPC. January 2018
3. Data on file. M360-L102 4-Year Clinical Study Report, 09 June 2016
4. Medicines360. A study of a levonorgestrel-releasing intrauterine system for long-term, reversible contraception. Available from: <https://clinicaltrials.gov/ct2/show/NCT00995150?term=medicines360&rank=1>

Note: In Hungary, the national phase of the variation procedure for 4-year use is still pending. In Austria, Belgium, Czechia, Germany, Ireland, Israel, Lithuania, Norway, Poland, Slovakia, Slovenia and United Kingdom the product is already licensed for 4-year use (DLP: April 24, 2018).

Predisposing factors of ovarian cancer

Petra Völgyesi¹, Erzsébet Valicsek², Iván Devosa³, György Bártfai¹

¹**Department of Obstetrics and Gynecology, University of Szeged, Szeged, Hungary**

²**Department of Oncotherapy, University of Szeged, Szeged, Hungary**

³**János Neumann University, Kecskemét, Hungary**

Introduction and Aims: Ovarian cancer is the second to most frequent gynecology malignant tumor, but its significance is even bigger, since by being the most malignant group, this is the leading cause of death among gynecology tumors. Its annual incidence is 200 000 in the world. In the early stages of developing, it does not cause any symptoms, in 70% of cases it is only diagnosed in late stage, and even that time the symptoms are not severe and usually atypical. Currently we still do not have any reliable screening test that could assess the possibility of ovarian cancer with good predictive measure even among women with average risk, so the difficultness of diagnosing it in early stage makes the risk factors even more important. Considering that the implantation of cells from the Fallopian tubes into the surface of the ovaries may play a role in involvement, we wanted to investigate the correlation between gynecology surgeries done prior to the involvement of the disease - such as unilateral and bilateral salpingo-oophorectomy, oophorectomy, hysterectomy focusing on the presence or absence of the Fallopian tubes - and the developing of ovarian cancer. We examined the total number of ovulations (ovarian micro traumas) throughout the patient's life, which was calculated for each patient considering the time of menarche and menopause, the frequency of menstruation, the number of childbirth, the duration of breastfeeding and the duration of oral contraception. In the future we would like to increase the number of both the case and the control groups in order to gain significant data for comparing the lifetime number of ovulations of the two groups. Furthermore, we monitored numerous possible risk factors as well, including age, duration of ovulation inducing therapy, time of first childbirth, duration of IUD usage, type of OC, duration of (post)menopause hormone replacement therapy, BRCA 1 and/or 2 mutations, previous tumorous diseases (breast, uterus, colon cancer), family history, certain gynecology diseases (endometriosis, ovarian cysts), obesity, smoking.

Materials and Methods: The documentation of the female patients previously diagnosed with and treated for ovarian cancer at the University of Szeged, Faculty of Medicine, Department of Oncotherapy was processed retrospectively. Parallel to this, a prospective analysis was started as well among the women treated for ovarian cancer at the outpatient care of the University of Szeged, Faculty of Medicine, Department of Obstetrics and Gynecology and Department of Oncotherapy, this was carried out by assisted filling out of printed questionnaires composed by us. (Case number: 308 female patients)

Our study was completed with involving a control group. (Number of the members of the control group: 200 women) The study is currently still on-going; we would like to expand it so that we can statistically compare the examined two groups.

Results: Ninetytwo percent of the 308 female patients suffering from ovarian cancer examined by us had both Fallopian tubes, 6% of them had only one tube and 2% of them had no tubes at the time of diagnosing them. In case of patients, who had no tubes when diagnosing them,

on average 22 years have passed between the removal of the Fallopian tubes and the time of the ovarian cancer diagnosis. In 5 patients (1.6%) ovarian cancer evolved while having no ovaries and in 17 patients (5.5%) one ovary was missing at the time of the diagnosis. In the case of one patient we experienced that ovarian cancer could evolve after the previous bilateral adnexectomy (done at the age of 33), and even more surprisingly for us, the tumor did not evolve within the following few years, but 35 years after the surgery. In the case of 4 patients (1.3%) ovarian cancer evolved on average 14 years following total hysterectomy and bilateral adnexectomy. Among them there was one patient, in whose case 25 years passed between the surgery (done at the age of 44) and the diagnosis of the ovarian cancer. We could not confirm the link between the development of ovarian cancer and the possible risk factors listed by literature, such as early menarche, nulliparity and late menopause. When examining 308 patients the average age of menarche was 13.52 years; the mean number of childbirth is 1.85; the mean age of menopause is 49.16 years. In the future we would like to compare the average number of ovulations in the sick, which is 384.98, to the number of ovulations in the control group. For this, however, we will need to increase the members of the control group.

Discussion: The Fallopian tubes that are present, or were kept during a previous gynecology surgery may play a significant role in the evolvement of ovarian cancer. We could not confirm the link between the development of ovarian cancer and the possible risk factors, such as early menarche, nulliparity and late menopause.

Conclusions: During our examinations it seemed to get confirmation that ovarian cancer may evolve in patients who previously underwent bilateral adnexectomy with or without total hysterectomy. For us it was shocking to realize that ovarian cancer can evolve 35 years after bilateral adnexectomy and 25 years after bilateral adnexectomy accompanied with total hysterectomy. The literature studied by us had no reports on cases with such long time intervals.

Keywords: ovarian cancer, Fallopian tubes, adnexectomy, ovulation

Intact Left Cornual Ectopic Pregnancy

Mileva Orelj-Popić, Ljiljana Mladenović-Segedi, Jovan Ugarković, Sonja Paljić

Clinical Center of Vojvodina, Clinic for Gynecology and Obstetrics, Novi Sad, Serbia

Introduction: Interstitial or cornual pregnancy counts for 2-4% of all ectopic pregnancies, it is located in the interstitial part of the fallopian tube. Cornual pregnancy pose a diagnostic challenge with a significant rate of complications. Our case was diagnosed by ultrasound, and treated surgically.

Case presentation: A 36-year-old patient gravid 2 para 1 at estimated gestational age (EGA) 19 weeks was referred to our clinic for amniocentesis after getting pathologic values of biochemical screening at EGA 12 and 17 weeks. An ultrasound examination found viable fetus in distended left uterine horn, with empty Douglas pouch.. Fetal biometry coresponded with the EGA. No associated abdominal pain, or vaginal bleeding was found. A diagnose of abdominal pregnancy was made. Patient was admitted for surgery. Intraoperative we found the uterus of normal size with distended left horn. In Douglas pouch ther was no free fluid. Cornual wedge resection was performed. The extracted fetus was 22 cm long with normal umbilical cord and placenta. The post-operative course went well and the patient was discharged in good condition. The diagnosis of cornual pregnancy was confirmed by pathohistological results.

Discussion: Early recognition of interstitial pregnancy is key for timely diagnosis and management. Its related mortality and morbidity is directly related to the length of gestational age. Cornual pregnancy in particular can be discovered with advanced gestational age even up to 16 weeks due to the adjacent supporting myometrial walls and good blood supply.

Early gestational maternal death in Hungary between 1997 and 2016.

Tamás Bitó¹, György M Csákány², Mária Jakó¹, Gábor Németh¹

1. Department of Obstetrics and Gynaecology, University of Szeged, Szeged, Hungary

2. Department of Obstetrics and Gynaecology, „Ferenc Jahn” South-Budapest Hospital, Budapest, Hungary

Objectives: Maternal mortality involves the death of a woman while pregnant or within 42 days of termination of pregnancy, irrespective of the duration and site of the pregnancy, from any cause related to or aggravated by the pregnancy or its management but not from accidental or incidental causes. Sometimes maternal death occurs in early gestation related to spontaneous or medical abortion. Maternal death due to the termination of unintended pregnancies may be prevented by safe and effective contraception.

The aim of our study was to analyze the occurrence of maternal deaths in early gestation (<24 gestational weeks) in Hungary during the last 20 years.

Methods: National data concerning maternal mortality, spontaneous and medical abortions were obtained from the Hungarian Central Statistical Office and concerning the causes of maternal death from the National Institute of Obstetrics and Gynaecology. Due to the low number of cases, maternal deaths were analyzed in 5-year periods: 1997-2001, 2002-2006, 2007-2011 and 2012-2016.

Results: The number of spontaneous abortions were similar (71,359 to 76,709 cases) in the examined 5-year periods, while there was a significant decrease concerning medical abortions (327,091 in 1997-2001 vs. 156,536 in 2002-2016). There were 23 early gestational maternal death in the examined period, of which 3 were not directly related to pregnancy.

Maternal deaths occurred in 5, 2, 10 and 6 cases in the examined 5-year periods, respectively. Maternal mortality related to spontaneous abortion were 2.8/100,000 and 6.8/100,000 in 1997-2001 and 2007-2011, respectively. Maternal mortality related to medical abortion were 0.3/100,000 and 2.1/100,000 in 1997-2001 and 2007-2011, respectively. There were no maternal death related to spontaneous or medical abortion in the other two 5-year periods.

Conclusion: Early gestational maternal death is rare, however represented the 4.5 to 14.9% of all maternal deaths in the examined 5-year periods. These were sporadic cases with high year to year variation without any significant tendency. However, five maternal deaths related to medical abortion could have been prevented by using a safe and effective contraceptive method.

Keywords: maternal death, spontaneous abortion, medical abortion

Determining factors of quality of life and assessing health status among 40-80 old population in South-Hungary

Anita Zubrecki

Child and Adolescent Psychiatry, Faculty of Medicine, University of Szeged, Szeged, Hungary

During the past few decades life expectancy has increased. According to the World Health Organisation's report by 2020 there will be more people aged 60 or older living in the World than children aged under 14 years old. It is essential to keep quality of life through ageing at a good level. Health is one of the most important determining factors of quality of life. There is a claim for simple measuring methods to assess people's health status. The importance of measuring handgrip strength as a health determining factor has got a lot of attention in the past few years. In our research 404 men and 327 women aged 40-80 years old were recruited in Szeged (Hungary). The results show that there is no significant relationship between self-reported health status and handgrip strength in the majority of the assessed population. We found determining, positive connection between body mass index and body fat percentage.

Supported by: OTKA NN110932 project Hungary

Quality of life assessment in elderly female and male population in the district of Szeged

Erika Török¹, Anita Zubrecki², Iván Devosa³

¹ Dept. of Obstetrics and Gynaecology, University of Szeged, Hungary

² Research Group on Health Science and Health Development

³ János Neumann University, Kecskemét, Hungary

The aim of this study was to investigate the effect of obesity, musculoskeletal health, nutritional factors and visual deficits on quality of life. During a four year period in 4 age groups (40-49, 50-59, 60-69, 70-79 years) altogether 731 (404 female and 327 male) patients have been investigated using questionnaire survey and measure physical and ophthalmological status. This poster would like to show the basic structure of this epidemiological study with special emphasis on the difficulties in recruit the patient. The results will be used in the further screening programmes and pinpoints the factors which are responsible for the self assessment of health status as one of the most important element of the quality of life.

Supported by: OTKA NN110932 project Hungary

Incidence and cultural aspects on the prevention and treatment of pelvic floor dysfunctions

F. Villani, B. Minopoli, A. Guglielmino, E. Moratti, A.L. Tataru, C. Furau.

Introduction: This paper collects epidemiological and economic evidence about urinary incontinence. Scientific studies show that about 10 years pass between the occurrence of pelvic floor disorders, primarily urinary incontinence, and the presentation to the doctor (C. Surcel et. al.). We conducted an observational study on postpartum patients of Arad hospital about prevention of those pathology

Objective: We wanted to analyze the woman's approach and her interest in dealing with these diseases in a preventive and / or rehabilitative way

Materials and Methods: We analyzed 83 women who have been proposed in the immediate postpartum to be a part of a study on the prevention and rehabilitation of the pelvic floor. Answer immediate and, for those who accept, at 45 days by phone. We asked all the women for reasons of interest and refusal.

Results: 44 women left right away mainly for 2 reasons: religion and lack of interest in prevention. 39 were recalled after 45 days to participate in the study and 18 were not interested because they did not have to whom to leave the children at home, because of distance or for family reasons. Only 21 reported interest and come at the first assessment to talk about rehabilitation.

Conclusions: The main obstacle is linked to cultural taboos for which they are led to ignore vaginal pathologies. Doctors today do not have the tools to help these patients. It is necessary to raise awareness among women beyond their cultural legacies regarding diseases of the pelvic floor in order to not force patients to have to resort to surgery when it is too late. Further studies are necessary.

Methods to increase the quality of life of women in diseases related to pelvic floor weakness.

F. Villani, E. Moratti, B. Minopoli, A. Guglielmino, A.L. Tataru, C Furau.

Introductions: These are the results of a multicentrum observative trial to determine the Quality Of Life (QoL) of women in dysfunctions related to pelvic floor (PF) weakness, also due to natural birth. It is highlighted that in the various approaches to pelvic floor rehabilitation the vaginal cone is the most economical, mainly to manage urinary incontinence (UI) and/or sexual dysfunctions. This approach allowed us to analyze the state of the disease before and after the training.

Objectives: Validating the QoL test before and after training for PF rehabilitation.

Material and Methods: We evaluated patients with a King's Health Questionnaire test 37 women (25-78 years old), which reported PF dysfunctions such as stress UI, urgency UI, mixed UI and sexual dysfunction. After explaining how to use the device at home the questionnaire was assessed on the first appointment before treatment and at the end of the 60/90 training days with the device.

Results: Out of 37 women involved, 10 dropped out due to lack of commitment. All 27 women left improved the test score.

Conclusion: A rehabilitative approach for women with PF dysfunctions is an important and excellent choice to give the woman a support, be it a medical device or only pelvic floor gymnastics, to improve their QoL and deal with the pathology.

Aspects regarding malpractice in laparoscopic gynecologic surgery

Mădălin Margan^{1,2}, Roxana Margan^{1,2}, Radu Neamțu^{1,2}, Ivana Eremici², Alin Popescu², Paul Panaitescu³, Dumitru Cătălin^{1,2}, Craina Marius^{1,2}

¹ **Department XII - Obstetrics and Gynecology, Neonatology and Perinatal Care, „Victor Babeș” University of Medicine and Pharmacy Timișoara, Romania**

² **„Bega” University Clinic of Obstetrics and Gynecology, Timișoara, Romania**

³ **„Iuliu Hațieganu” University of Medicine and Pharmacy, Cluj-Napoca, Romania**

Malpractice is becoming a serious healthcare problem worldwide, as the relationship between the doctor and the patients has suffered significant transformations. In spite of the fact that every medical and surgical specialty is exposed to the risk of malpractice, obstetrics and gynecology is considered to be one of the most affected. A lot of studies and surveys concluded that that the highest number of medical malpractice reported were from obstetrics and gynecology, orthopedics, neurosurgery, and general surgery. Nowadays, laparoscopy occupies an important role in the diagnosis and treatment of a variety of gynecological disorders. It is an extremely useful tool because of its important advantages such as: less pain after surgery, shorter hospital stays, faster healing, lower risk of infection etc. However, laparoscopic interventions are associated with a significant number of risks and complications, which is why they require experienced surgeons and well-informed patients. This awareness of both sides will have a positive impact in reducing patient morbidity and mortality, and of course avoid the stress and anxiety of litigation, which has become extremely important. All these medical aspects should be seriously taken into considerations, as we can face important complications while performing laparoscopy, which cannot be whatsoever neglected. These complications can refer to either entry-related complications or others which may occur during surgical intervention, such as: injuries of the bowel, vessels, nerves or urinary tract. In this paper, we will discuss some of the most important complications, their incidence, modalities of prevention and medico-legal aspects, in order to improve their management in our daily practice.

The importance amniotic fluid on fetal growth and development

Radu Neamțu^{1,2}, Mădălin Margan^{1,2}, Roxana Margan^{1,2}, Ivana Eremici², Alin Popescu², Ion Neamțu³, Dumitru Cătălin^{1,2}, Craina Marius^{1,2}

¹ Department XII - Obstetrics and Gynecology, Neonatology and Perinatal Care, „Victor Babeș” University of Medicine and Pharmacy Timișoara, Romania

² „Bega” University Clinic of Obstetrics and Gynecology, Timișoara, Romania

³ „Titu Maiorescu” University of Medicine and Pharmacy, București, Romania

Amniotic fluid is the clear liquid surrounding the fetus in the amniotic cavity. This fluid plays a key role in maturation of the fetus and prevention of diseases, and it does so, by the virtue of bioactive compounds present in it. Any alteration in amniotic fluid can impact the health of the fetus and/or the mother negatively. This paper aims at highlighting the role of various ions present in the amniotic fluid, on fetal development and maturation.

Almost at the same time as the implantation, an extracolemic cavity is produced that forms the amniotic space. During the entire pregnancy, the growing fetus and amniotic fluid are both enveloped in the amniotic sac. Initially, the maternal plasma mainly contributes to the formation of the amniotic fluid and reaches the fetus by traversing the fetal membranes. However, as the placenta is formed, the plasma from the mother’s blood crosses the placenta and reaches the fetus, contributing to the amniotic fluid. As the fetal skin is not keratinized in early pregnancy, there is diffusion of amniotic fluid across the fetal skin, and it is similar in composition to the plasma of the fetus. However, post-keratinization of the fetal skin, the absorption of the fluid takes place through the fetal gut.

Around 8 weeks of pregnancy, when fetal kidneys achieve the ability to make urine, it also contributes to the formation of the amniotic fluid. The quantity and composition of the amniotic fluid is tightly regulated by a perfect balance of exchange between the mother, fetus, and placenta.

The amount of amniotic fluid increases steadily to reach a maximum of approximately 400-1200 ml at 34-38 weeks, and then subsequently starts declining. At 40 weeks, the volume of amniotic fluid is approximately 800 ml and continues to decrease till the pregnancy continues.

Cervical cancer in Arad county Romania

**Ana-Liana Tataru^{1,2}, Cristian Furău^{1,2}, Loredana Roşu¹, Casiana Stănescu^{1,2},
Cristina Onel^{1,2}, Voicu Daşcău^{1,2}, Gheorghe Furău^{1,2}**

¹ Arad County Clinical Hospital, Arad, Romania

² “Vasile Goldis” Western University of Arad, Romania

Cervical cancer is a major worldwide health problem that can be prevented by using a simple exam, a cervical-vaginal cytology or Pap smear. Romania has the highest incidence and mortality from cervical cancer in Europe. Romanian people have a strong fear towards cancers and, paradoxically, toward screening measures for cancer.

Objectives: To determine the efficiency of Romanian Health Programs regarding cervical cancer.

Materials and Methods: The last six decennial periods were analysed from the point of view of registered cervical cancers cases, using all available types of official statistical data for Arad County region of Romania (n=2333, between 1907-2017).

Results: Between 1907- 2017, in this 110 years, there have been reported 7593 cases of genital female cancers, of which 30,73 % of them (meaning 2333 cases) were cervical cancers. The three years period from 2006 till 2009 was the highest incidence for this pathology, reaching the number of 116 new cases (especially in 2007). Squamous cell carcinoma (SCC) is one of the most frequent histological subtypes of cancer (73,8%) followed by adenocarcinoma (11,4%). According to the 1990's report, the in situ phase, is more frequent for the registration of cervical cancer, after 1991 the registration has been 1:13. The incidence of cervical cancer for Arad region is the greatest for aged 40-49 years, which is surprisingly in general context where the peak age of cancer diagnosis is population aged 25–29 years.

Conclusion: Cervical cancer control in Romania needs imperative actions to be taken, focused mainly on the highest risk age-categories and on building a positive attitude about cancer screening, knowing that a positive attitude is never automatic.

Keywords: cervical cancer, incidence, early detection

Arad's Maternal and Infant Care Project for communities in poverty

Loredana Roșu¹, Cristian Furău^{1,2}, Ana-Liana Tataru^{1,2}, Gheorghe Furău^{1,2}, Casiana Stănescu^{1,2}, Cristina Onel^{1,2}, Voicu Dașcău^{1,2}

¹ **Arad County Clinical Hospital, Arad Romania**

² **“Vasile Goldis” Western University of Arad, Arad, Romania**

Introduction: Despite the economic growth Romania has passed in the last few years, 20 % of the population is living below the poverty line and the most representative national minority living in the country under these conditions are the Roma minority.

Objectives: To improve the awareness of, access to and quality of preventive and curative health services with a view to reducing infant mortality and morbidity, maternal mortality and morbidity, promoting healthy child development up to the age of 3 years, by providing pre and postnatal care amongst poor and marginalized communities in the County of Arad

Methods: A cooperative group from midwife, GP and obstetrician from Arad Hospital and „Vasile Goldis” University together with Karolinska experts and Networks NGO volunteers, developed a protocol for improving maternal and infant care.

Results: Midwives together with Networks representatives and social workers will collaborate to highlight the pregnant women and after a short evaluation, to fit them into a high risk or low risk pregnancy, and get them to a obstetrician (hospital) for an ultrasound and blood samples. Low risk pregnancies will need 2 visits at the OB.specialist and the midwife can manage the pregnancy, meanwhile the high risk ones will need a special approach. The birth will take place at the hospital assisted by the midwife and the obstetrician.

The postpartum period (4-6weeks) will be monitored by the GP and the midwife in the community, and the patient should come to the obstetrician for a full gynecological check-up after 6 weeks postpartum. The newborn and small child (till the age of 3) will be taken care by the midwife and GP, who will also give breastfeeding advice and watch the vaccination chart to the completed as in the national vaccination programme.

Conclusion: The project our team developed should be appropriate to be reapplied in any other region and gain social sustainability with the aim to reduce maternal and infant mortality and morbidity.

Keywords: poverty, minority, medical access, maternal and infant care

The Clinical Impact of the HOMA Index in Early Detecting the Risk of Preeclampsia - comparison between preeclampsia and nonpreeclampsia pregnant women

Cristina Onel¹, Gheorghe Furău¹, Cristian Furău⁴, Voicu Dașcău¹, Liana Tătaru³, Casiana Stănescu², Mircea Onel⁶, Amarin Popa⁵

¹“Vasile Goldiș” Western University of Arad, Faculty of Medicine, Department of Obstetrics-Gynaecology, 86 Liviu Rebreanu, Arad, Romania

²“Vasile Goldiș” Western University of Arad, Faculty of Medicine, Department of Anatomy, 86 Liviu Rebreanu, Arad, Romania

³“Vasile Goldiș” Western University of Arad, Faculty of Medicine, Department of Pathophysiology, 86 Liviu Rebreanu, Romania

⁵University of Oradea, Faculty of Medicine, 10 Piata 1 Decembrie, Romania

Women with preeclampsia, independent of obesity and glucose intolerance, exhibit insulin resistance during pregnancy. The purpose of the present study is to determine whether early diagnosis of insulin resistance during pregnancy can predict preeclampsia. PE is known to have a higher prevalence in women with Diabetes Mellitus. Both the gestational diabetes and the preeclampsia are regarded as major pregnancy complications both for the mother and for the foetus. The pathological mechanism, implying PE at the women with diabetes mellitus, is not fully comprehended. The homeostasis model assessment of the insulin resistance (HOMA-IR) is used to define the insulin resistance as predictor for the cardiovascular diseases.

The study sample was formed of women, until now 150 women, from which 83 samples were processed.

Of them, 7.22% had abortions, 10.8% were diagnosed with various forms of HT-PI (hypertension- pregnancy induced), and 81.98 % did not present hypertension.

Of the 92.78% evaluated pregnancies with the pregnancy in progress, 61.03% had delivered until now.

Our data shown that the pregnant women who had abortions had the lowest values of PAPP-A, followed by those who developed hypertension, also the pregnant women who had abortions had most elevated values of HOMA-IR, and, again, the pregnant with HT-PI followed them in results. Consequently, these data show that, during the first semester of pregnancy, the higher resistance to insulin associated with low values of PAPP-A increase the risk to develop pregnancy induced hypertension.

Acknowledgements: The work was funded from the grant no. PI/3/21.07.2014. “The Clinical Impact of the HOMA Index in Early Detecting the Risk of Preeclampsia in the Pregnant Woman”

Corresponding author: gfurau@yahoo.com

Hematohydrohysteroocolpos with vaginal atresia - case report

Petru Chitulea¹, Rares Gherai²

¹ Department of Obstetrics and Gynaecology, University of Oradea, Faculty of Medicine and Pharmacy, Oradea, Romania,

² University of Oradea, Faculty of Medicine and Pharmacy, Oradea, Romania

Abstract: Hydrocolpos is a rare condition, clinically obvious at birth, or within the first few weeks of life and it appears as an abdominal mass associated with the absence or abnormality of the vaginal opening. A premature 25 days old female new-born was diagnosed with hematohydrohysteroocolpos, imperforate hymen. After the surgery, the evolution is positive and the patient is released from the hospital in a good general state.

Keywords: imperforate hymen, vaginal atresia, hematohydrohysteroocolpos of a newborn

Introduction: Hymenal anomalies result from incomplete degeneration of the central portion of the hymen. Variations include imperforate, microperforate, septate, and cribriform hymens. Although most of these variants are not clinically significant, hymenal anomalies require surgical correction if they block vaginal secretions or menstrual fluid, interfere with intercourse, or prevent treatment of a vaginal disorder.

Imperforate hymen represents a persistent portion of the urogenital membrane. It occurs when the mesoderm of the primitive streak abnormally invades the urogenital portion of the cloacal membrane. It is one of the most common obstructive lesions of the female genital tract. When mucocolpos develops from accumulation of vaginal secretions behind the hymen, the membrane is seen as a shiny, thin bulge. The distended vagina forms a large mass that may interfere with urination and at times may be mistaken for an abdominal tumor. Topical anesthetic is used to prevent discomfort to the newborn, and the central portion of the obstructing membrane is excised. When imperforate hymen is corrected in infants, the central portion of the membrane is excised; sutures usually are not necessary.

If missed during the newborn period, imperforate hymen often is not diagnosed until an adolescent presents with complaints of primary amenorrhea and cyclic pelvic pain. It may present as back pain or difficulty with defecation or urination secondary to mass effect from vaginal distention. Inspection of the vulva may reveal a purplish-red hymenal membrane bulging outward as a result of accumulation of blood above it (hematocolpos). Blood may fill the uterus (hematometra) and spill through the fallopian tubes into the peritoneal cavity. Endometriosis and vaginal adenosis are known but not inevitable complications.

Repair of imperforate hymen is facilitated if the tissue has undergone estrogen stimulation and the membrane is distended. When the procedure is performed in an adolescent, a large central portion of the membrane should be removed because the edges of a small incision may coalesce, allowing the obstructing membrane to reform.

Hydrocolpos is an anomaly and a rare condition which occurs in new-born female infants as the result of the stimulation of maternal estrogens; it consists of atresia of the vaginal outlet and excessive secretion of the cervical glands and produces a midline mass and building at the

introitus.

Regarding the etiology, we find two theories in the academic literature, both of which may be regarded as correct:

- an imperforate hymen, which is the true cause;
- a thick membrane is responsible for it (considered to represent an atresia, similar to that of imperforate anus)

Hydrocolpos is clinically evident at birth, or within the first few weeks of life, and it appears as an abdominal mass associated with absence or abnormality of the vaginal opening. The diagnosis is confirmed by abdominal ultrasound and CT scan.

Females with vaginal atresia lack the lower portion of the vagina, but otherwise have normal external genitalia. The embryonic origin of this condition is presumed to involve failure of the urogenital sinus to contribute its expected caudal portion of the vagina (Simpson, 1999). As a result, the lower portion of the vagina, usually one fifth to one third of the total length, is replaced by 2 to 3 cm of fibrous tissue. In some individuals, however, vaginal atresia may extend to near the cervix.

Since most women with vaginal atresia have normal external genitalia and upper reproductive tract organs, this condition does not often become apparent until the time of expected menarche. Adolescents generally present shortly after physiologic menarche with cyclic pelvic pain due to hematocolpos or hematometra. On physical examination, normal breast and pubic hair development is present. The perineum is usually normal, with normal secondary sex characteristics with a hymeneal ring and beyond the ring, a vaginal dimple or small pouch. A rectoabdominal examination confirms the presence of midline structures. Additionally, sonographic or MR imaging will display upper reproductive tract organs. Of these, MR imaging is a more accurate diagnostic tool, as the length of the atresia, the amount of upper vaginal dilatation, and the presence or absence of a cervix can be identified. Laparoscopy, however, is necessary for diagnosis when the anatomy cannot be fully evaluated with radiographic studies. For example, Economy and associates (1998) reported that MR imaging has only 31-percent sensitivity for the detection of uterine structures in patients with vaginal agenesis. About one third of women with vaginal atresia have associated urologic abnormalities.

Vaginal atresia is distinct in clinical and embryonic characteristics from transverse vaginal septum. In patients with transverse vaginal septum there is a well-developed vagina in which a thick intervening septum separates the lower from the upper vagina. Conversely, in those with vaginal atresia, fibrous tissue develops in place of the vagina. In some, nearly the entire span beginning at the perineum and extending cephalad to the cervix may be fibrotic. Identification of the cervix in such cases distinguishes vaginal atresia from mullerian agenesis.

Case Report: A premature new-born female, 25 days old, is admitted in the paediatric unit for the bio-clinical re-evaluation and a specialised treatment, having previously been diagnosed with congenital pelvic tumour.

The medical history of the illness reveals that starting from the intrauterine life, affirmative, a tumour mass is being observed via ultrasound - approximately 5 cm in diameter, situated in the abdominal cavity, right next to the uterus, interpreted as a cystic ovarian tumor by the obstetrician. Postnatally, the new-born presents a good general state, with a balanced respiratory and cardiovascular function, present bowel transit, present diuresis. At the ultrasound check-

up, the presence of a tumour mass in the intra-abdominal cavity is confirmed, having a mixed parenchymatous-fluid aspect, hard to appreciate as being part of the organ.

In order to identify the nature and the origin of this mass, a CT scan is being performed that shows images suggesting a cystic pelvic-subperitoneal mass. It is important to mention that the examinations conducted in the laboratory have not highlighted any alterations of the renal function.

The general clinical examination reveals a voluminous distended abdomen which highlights a tumour mass in the hypogastrium with the palpation of a firm mass, adherent to the subjacent plans, painless, unique

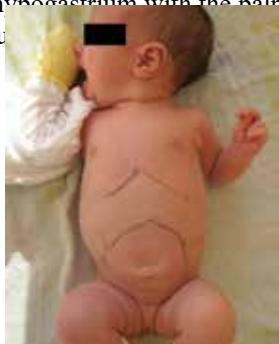

Figure 1. - Abdominal pelvic tumor size

The abdominal ultrasound highlights a space occupying abdominal-pelvic process, with fluid content, a possibility of an increased volume of the uterus, with difficult limits to set, with hematocolpos and bilateral hydro nephrosis with secondary compression. A specialised team, comprised of a surgeon and an oncologist, decide the timing of the procedure in order to precisely establish the affected organ through MRI studies. The images provided by the MRI advocate the diagnosis of a primary germinal tumor, with primary and secondary effects on the surrounding structures.

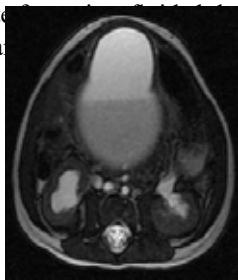


Figure 2. – MRI Section

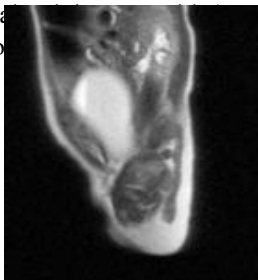

Figure 3. – MRI Section

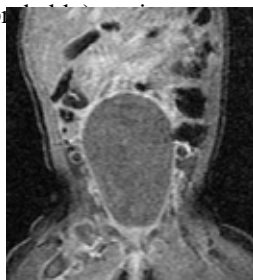


Figure 4. – MRI Section

The laboratory examination revealed the changes: increased levels of Lactate dehydrogenase (LDH) – 267u/l, AFP alpha-fetoprotein 486.64 ng/ml, total serum proteins 5.35 g/dl, serum creatinine 0.20 mg/dl and a decrease in urea nitrogen 9.27 mg/dl.

As a result of these investigations, clinical and paraclinical, after the gynaecological examination which highlights the imperforate hymen, we set the diagnosis of hematohydrohysterocolpos, imperforate hymen and after a thorough preoperative preparation, we performed the surgery. A No 18 needle was inserted into the membrane at the introitus, and 20 ml of haematic, brownish liquid was removed, when we observed a vaginal atresia. Then, on needle path, we performed

a straight and deepness incision of approximately 1 cm at the introitus membrane, at a distance from the urethra, bladder and the rectum in order to not sever them.

On the colpos incision, we evacuated about 200 ml of haematic, brownish liquid. At the end, a drainage tube was fixed through the incision in order to ensure the complete evacuation of the intraperitoneal fluid and after 7 days

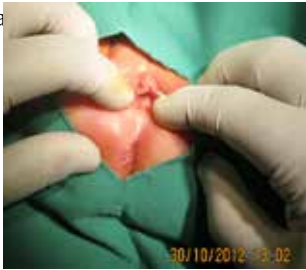

Figure 5. – Intraoperative view

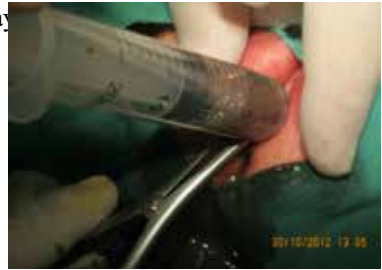


Figure 6. – Intraoperative view

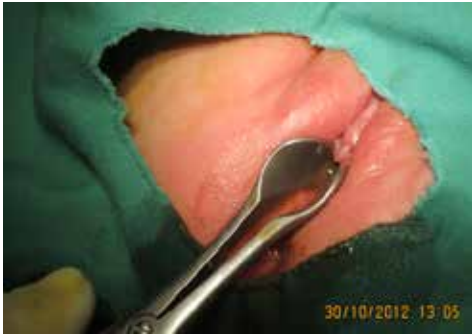

Figure 7. – Intraoperative view

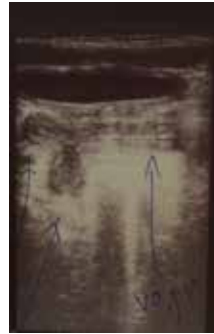

Figure 8. – Ultrasound after surgery

The follow-up abdominal ultrasound performed in the first day after the surgery highlights an decreased of the bilateral hydro nephrosis from stage II, prior to the surgery, to stage I - a uterus significantly reduced in size, without any fluid in it. Under antibiotic cover the evolution is positive and the patient is released from the hospital in a good general state 10 days after surgery. After this, the child is being periodically followed up to monitor normal subsequent development.

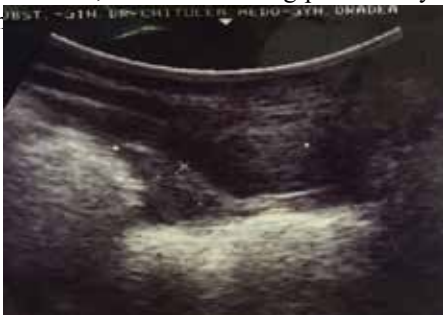

Figure 9. - The ultrasound performed 2,5years after surgery.

Conclusions: The imperforate hymen and/or atresia of the distal vagina can be caused by fluid and blood successive to the genital crisis of the new born baby so that the hematohydrohysterocolpos to produce pseudo cystic pelvic tumors susceptible to compress both ureters leading to hydronephrosis.

The advisable/opportune surgical treatment that involves the evacuation has, including, the fetal vital indication.

The authors declare no conflict of interest.

Bibliography:

1. Adaletli I, Ozer H, Kurugoglu S, et al: Congenital imperforate hymen with hydrocolpos diagnosed using prenatal MRI. *AJR Am J Roentgenol* 189(1):W23, 2007
2. Decherney A.H. et all, *CURRENT Diagnosis & Treatment Obstetrics & Gynecology*, Tenth Edition, 2012 Sept., Cp.34.
3. Lim YH, Ng SP, Jamil MA: Imperforate hymen: report of an unusual familial occurrence. *J Obstet Gynaecol Res* 29:399, 2003 [PMID: 14641689]
4. Pitkin J. et all, *Obstetrics and Gynaecology, Developmental and paediatric gynaecology*, 2003, pg. 89.
5. Plumb RT, Kelly JR, Dillon JR. Hydrocolpos in a Newborn Child. *Western Journal of Medicine*, 1963 Oct; 99(4): 263–265.
6. Schorge et all, Section 2 Reproductive Endocrinology, Infertility, and the Menopause > Chapter 18. *Anatomic Disorders – Vaginal agenesis*, Williams Gynecology, 1 edition, April 2008
7. Sidatt M¹, Ould Sidi Mohamed Wedih A, Ould Boubaccar A, Ould Ely Litime A, Feil A, Ould Moussa A. Hydrocolpos and hydrometrocolpos in newborns. *PubMed* 2013 Feb;20(2):176-80.

Malignant peritoneal mesothelioma with a long term postoperative survival - case report

Petru Chitulea¹, Rares Gherai²

¹ Department of Obstetrics and Gynaecology, University of Oradea, Faculty of Medicine and Pharmacy, Oradea, Romania

² University of Oradea, Faculty of Medicine and Pharmacy, Oradea, Romania

Abstract: Malignant peritoneal mesothelioma is a form of cancer originating from the lining cells of the pleural and peritoneal cavities, as well as the pericardium and the tunica vaginalis. The incidence of malignant mesothelioma is increasing worldwide because of the use of asbestos. However, in Romania the asbestos-containing products that are installed or in service may be used until the end of their life cycle. This study reports a 34-year-old patient with a malignant mesothelioma of the peritoneum of foamy cell subtype, involving the omentum and left ovarian surface, where complete surgical cytoreduction seems to be a rational therapeutic approach, considering that there are no signs of relapsing tumour.

Keywords: malignant peritoneal mesothelioma, asbestosis, surgical cytoreduction

Introduction: Malignant peritoneal mesothelioma (MPM) is considered a rare form of intraperitoneal, aggressive neoplasm, strongly related to previous asbestos exposure [1]. Also it is considered as a form of cancer originating from the lining cells (mesothelium) of the pleural and peritoneal cavities, as well as the pericardium and the tunica vaginalis [2]. Its distribution may be uni- or multifocal or may involve the lining cells in a continuous manner [3]. Malignant mesothelioma of the peritoneal cavity accounts for only 10-20% of all mesotheliomas and usually involves elderly or middle age males, often with a previous history of asbestos exposure [4].

Epidemiology: Regarding the history of malignant peritoneal mesothelioma, we can see that before 1950, it was so rare that some pathologists even questioned its existence [5]. However, the incidence of malignant mesothelioma is increasing worldwide because of the use of asbestos after the Second World War as a building material. Although its use was widely abandoned in the Western world in the 1980s, the long latency period between exposure to asbestos and onset of mesothelioma, which can range from 15 to 60 years, meant that the mortality rates from mesothelioma have continued to rise [3:1,2].

In the 1960s a mesothelioma register was set up in the UK to record the mortality rates from mesothelioma and to try to identify the incidence of tumour development without known occupational exposure. It is predicted that around 90,000 deaths will occur from mesothelioma by 2050 [3:2; 6]. Manzini, in the clinical records of 15 patients affected by MPc, observed at the Monfalcone Hospital from 1982 to 2003, that asbestos exposure was present at 12 patients [1]. La Vecchia *et al* [7] used death certificates from 8 European countries to predict peak mortality between 2010 and 2020. Also a peak incidence in France is expected in 2030 [8] and is projected for 2012-2024 in Italy [9]. In Romania, by Government Decision (GD) of 15.04.2006 asbestos was outlawed, however GD no 734 / 2006 extended the use of asbestos thus: “asbestos-containing products that have been installed or were in service before 1 January 2005 date may be used until the end of their life cycle “.

Clinical presentation: The studies on MPM report some limited series of single cases; in this condition, the initial symptoms on clinical presentation are poor, atypical, non-specific and the level of clinical suspicion is relatively low [10, 11]. Moore *et al*, consider mesothelioma primarily as a disease of adults, usually presenting in the fifth to seventh decades of life with 70–80% of cases occurring in men [3].

Manzini identified three different types of clinical presentation of MPM (sometimes assembled in different associations):

- the classical type - characterized by abdominal swelling due to ascites and/or an abdominal mass often associated with abdominal pain and weight loss, in 6 cases;
- the surgical type - characterized by a surgical emergency, in 5 cases;
- the medical type - characterized by fever, diarrhoea, weight loss, and acute phase reactant changes, in a clinical picture resembling that of intestinal inflammatory bowel disease, in 4 cases [1:1,2].

However, it is hard to make an initial diagnosis; this can be confirmed by accurate history,

examination, imaging studies [3] and histopathological findings of hyaluronic acid level in the ascitic fluid [12].

Case Report: The 34-year-old patient, non-smoker, was admitted to the Gynecology Department of the County Emergency Clinical Hospital Oradea, Romania, with pain in the lower abdomen, weight loss, abdominal distension, ascites, and loss of appetite. The clinical examination highlights pale-earthly skin, muscular hypotonia, and ascites. The gynecology exam, manual vaginal exam and examination with valves highlight multiparous cervix (multigravida), with periorificial injury, and right adnexal mass.

The CT scan exam (Fig.1,2,3) reveal a large quantity of ascites, multiple intra-abdominal nodules sized 2-10 cm and a right ovarian mass. Moreover, the tumour marker CA 125 shows increased values. After these clinical and paraclinical findings, an ovarian neoplasm with ascites is suspected and surgical intervention is decided.

We are conducting a median pubo-supraumbilical laparotomy, and during the inspection of the peritoneal cavity a tumour mass of 10x9x7 cm is revealed, solid, friable, yellowish (like sulphur), cauliflower-shaped, with epiploic origin (which was the suspected right adnexal mass) and which invades the superficial cortex of the left ovary (Fig.4); moreover, multiple epiploic nodules are showing the same features, with the greatest diameter of 2.5 cm (Fig.5); we also found about 5 litres of ascitic fluid, a uterus of normal aspect and size, the right ovary with a normal aspect and a cystic left ovary. We performed an omentectomy, a partial resection of the left ovary, peritoneal biopsy and about 20 ml of ascitic fluid was collected for the cytology.

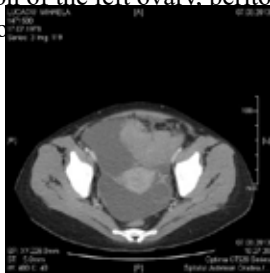


Figure 1. Imagine TC

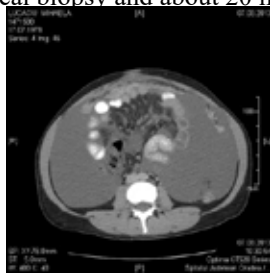

Figure 2. - Imagine TC

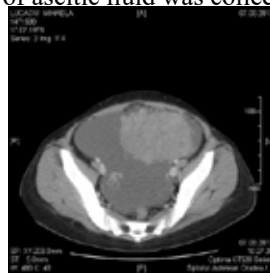

Figure 3. - Imagine TC

Macroscopical findings: Intraoperative multinodular tumour, with the biggest solid nodule of 10 cm in diameter, firm, rubbery, white-yellowish, with necrosis and other multiple omental nodules with the same features.

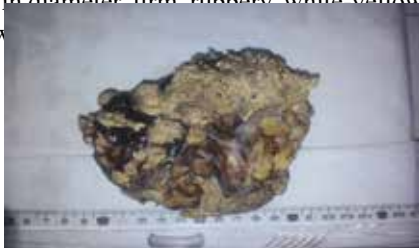

Figure 4. - Intraoperative multinodular tumor, with the biggest solid, nodule of 10cm in diameter and multiple nodule with the same aspects with the diameter between 2,5 and 1cm

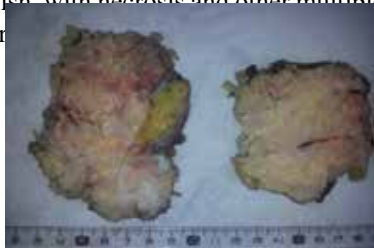


Figure 5. - Section of nodule with 10cm in diameter

Microscopical findings: All the nodules previously described had the same morphology: architecturally, the tumour has a solid, papillary and tubule-papillary growth pattern, although small nests and cords of tumour cells may be seen. In contrast to serous tumours (which is the more frequent type of intraperitoneal tumour in women), the papillary pattern is non-hierarchical and cellular budding from the surface of the papillae is inconspicuous. The core of the papillae is often hyalinised and contains foamy histiocytes. The tubules usually are small and round. The tumour cells are of epithelial type, and retain a resemblance to mesothelial cells with a polygonal, cuboidal low-columnar shape, with moderate amounts of eosinophilic cytoplasm. Tumour cells with cytoplasmic vacuoles are sometimes present (Figure 6), focally suggesting an adenomatoid tumour. Mitotic figures are inconspicuous. Invasion of sub peritoneal tissue is present, the tumour dissecting into the omental fat. The stroma are prominent, from hyalinised to desmoplastic. Tumour necrosis is obvious. The immunohistochemical features are very helpful even if no single immunohistochemical stain is diagnostic. Positivity of tumour cells for Calretinin (Figure 7), Podoplanin and D 2-40, also negativity for p53 oestrogen receptors supports the diagnosis of malignant peritoneal mesothelioma.

Also, histopathological examination excluded the following lesions:

- atypical mesothelial hyperplasia (more commonly an incidental microscopic finding of a small solitary or multiple nodules; the mesothelial cells contain cytoplasmic vacuoles which stain for acid mucin); desmin-positive and EMA, p53 negative;
- reactive fibrosis (most commonly in desmoplastic malignant mesothelioma);
- well-differentiated papillary mesothelioma (often small, solitary, non-invasive; typically pure papillary pattern consists of fibrous cored papillae lined by a single layer of benign-appearing, mitotically inactive mesothelial cells);
- adenocarcinoma with diffuse peritoneal involvement, including metastatic serous adenocarcinomas and serous carcinomas of primary peritoneal origin (histologically, the serous tumour presents a complex papillary pattern, with the papillae containing fibro vascular cores, covered by stratified epithelial cells and cellular buds, often with single cells exfoliating from the papillae; mitotic figures are conspicuous, marked nuclear atypia; psammoma bodies occur frequently; p53+ immunoreactivity; serous carcinomas are usually immunoreactive for MOC-31, Ber-EP4 and oestrogen receptors; positivity for calretinin, CK 5/6, podoplanin and D2-40 favours peritoneal malignant mesothelioma).

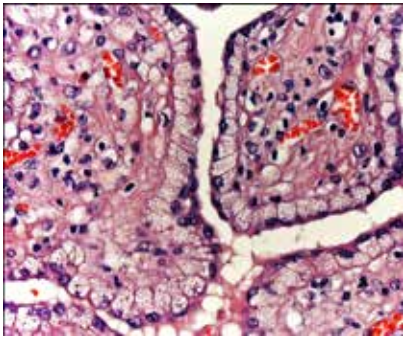


Figure 6. Mesothelioma H-E

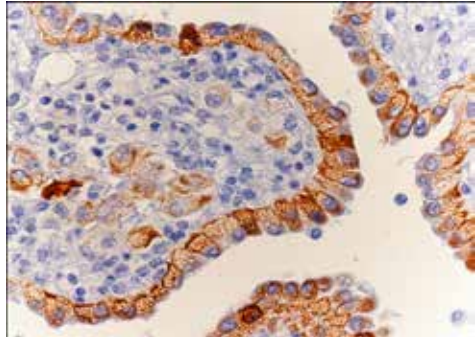


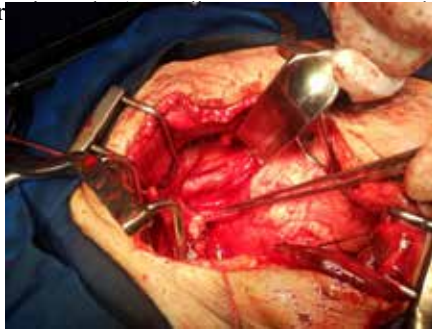
Figure 7. Mesothelioma IHC: CK5/ 6

After a clear diagnosis of malignant mesothelioma of the peritoneum involving the omentum and left ovarian surface was made, we conducted an epidemiological investigation. We found that the roof of the patient's house was made of asbestos cement boards, corroded, patient collecting water rain drain on them for domestic use, being constantly exposed to inhalation of asbestos particles. The patient was directed to oncology services, but unfortunately she declined any further oncological treatment.

Seven months after the surgical intervention, the patient presented to the Gynecology Department of the County Emergency Clinical Hospital Oradea, Romania, with a generally altered state, the clinical examination revealing umbilical hernia, abdominal distension, ascites, modified bowel habits; taking into consideration the diagnosis of malignant peritoneal mesothelioma, it was decided to perform another surgery, for a 'second look' and for surgical cytoreduction after having conducted a thorough preoperative preparation.

We conducted a median iterative pubo-supraumbilical laparotomy. During the examination of the peritoneal cavity, almost 2 litres of ascitic fluid were collected for cytology; we also found adhesions of the recto-sigma to the left adnexa, intestinal loops to the parietal peritoneum and the caecum to the uterus. After the extensive adhesiolysis, the full hysterectomy was performed with a bilateral salpingo-oophorectomy. After the examination of the pelvic peritoneum, a tumour mass, of approximately 1 cm diameter is observed at the bottom of the Douglas pouches, which is removed. Moreover, we perform a lymphadenectomy to an external iliac lymph node, to a right obturator lymph node and the extirpation of a retrocrual tissue. In the next step we examine the parietocolic gutters, both diaphragmatic cupolae are being examined and palpated as well as the surfaces of the spleen and the liver. Because of the high risk of pneumothorax, no peritoneal biopsy was performed from the right hemidiaphragm and there have been no macroscopically identified abnormalities. In order to continue the process, the colon was examined next, from the rectum to the caecum, removing a perirectal tumour of approximately 7/5 mm. Examining the small intestine, from the ileocaecal valve to the Treitz ligament, we did not find any suspicious macroscopical abnormality.

A mesenteric tumour appears to be an omphalocele.



Moreover, we perform an omphaloectomy.

Figure 8. - Intraoperative view

The microscopical examination reveals the tumour proliferation in the following fragments: a perirectal tumour (7x5 mm node), peritoneum (diffusely infiltrated with a tumour of 5x5 mm), a mesenteric nodule (epiploic appendix of 10/6 mm), the serosa of the uterine corpus at the bilateral adnexa (serous tubal, the surface of the ovary and the superficial cortex – infiltrated); the cutaneous fragments sent separately and the umbilical scar being coated thoroughly by the peritoneal serosa, diffusely infiltrated by the tumour cells with the aspect of malignant mesothelioma. The pelvic lymph node: one in the right external iliac area and one in the right obturator area reveal a sinus histiocytosis; the retrocrural tissue – fat. Cervix: chronic cervicitis and endocervical microglandular hyperplasia without atypia. Uterine corpus: endometrium in the mid proliferative phase. Adenomyosis. Uterine serosa infiltrated with tumour cells. Adnexa: bilateral ovarian cystic follicles and the superficial cortex infiltrated with tumour cells; the left ovary present a foreign-body giant cell reaction.

In March 2015, the patient was admitted to the surgical department with a generally altered state, accusing generalised abdominal pain, nausea, vomiting, postoperative eventration strangled by necrotic tissue at the eventration site and the lack of bowel transit. After a clinical and paraclinical analysis and an appropriate preoperative preparation, on the 12th of March 2015 we performed another intervention and found a generalised faecal peritonitis, the necrosis of an ileal loop in the eventration pouch and extensive adhesions syndrome. After the removal of the necrotic ileal loop with the LL, an ileoileal anastomosis and the cure of the monoplane eventration, the postoperative evolution has been disappointing, calling for another exploratory intervention on the 20th of March 2015, when we found skin necrosis along with fixed evisceration, an anastomotic fistula and obstructive faecal peritonitis in pelvis. The anastomosis and ileostomy were performed, after which a Pezzer's catheter was introduced in the ileostomy, being ultimately removed. At the histopathological examination in the sections analysed, there is necroinflammatory activity on the serosa of ileum with a rich inflammatory polymorph infiltrate, fibrin deposits, granular tissue and unspecified granulomatous inflammatory reaction. In the examined fragments, in the usual H-E coloration, there cannot be seen any tumour cells.

On 12th of September 2015, the patient presents at the surgery department for a check-up and after the clinical and paraclinical examination, no signs of relapsing tumour were found.

On July 2016, the patient returns for a clinical evaluation, examination showing a good general condition without any clinical signs of relapse.

Conclusions: It is difficult to diagnose malignant peritoneal mesothelioma diagnose preoperatively because it can be easily confused with *an ovarian tumour*, a thickening of the peritoneum and of the mesentery, the presence of the intra-abdominal multiple nodules and ascites not being characteristic. Complete surgical cytoreduction seems to be a rational therapeutic approach in the case of the malignant peritoneal mesothelioma.

The authors declare no conflict of interest.

Bibliography:

1. Manzini VP. Malignant peritoneal mesothelioma. *Tumori* 2005; 91: 1-5.
2. Jett J, Aubry M. Malignant Pleural Mesothelioma. *Clinical Respiratory Medicine. Mosby* 2nd edition. 2008, 735-741.
3. Moore AJ, Parker RJ, Wiggins J. Malignant mesothelioma. *Orphanet Journal of Rare Diseases* 2008, 3:34.
4. Baker PM, Clement PB, Young RH: Malignant peritoneal mesothelioma in women: a study of 75 cases with emphasis on their morphologic spectrum and differential diagnosis. *Am J Clin Pathol* 2005, 123:724–737.
5. Carbone M, Bedrossian CW: The pathogenesis of mesothelioma. *Semin Diagn Pathol* 2006, 23:56-60.
6. Hodgson JT, McElvenny DM, Darnton AJ, Price MJ, Peto J: The expected burden of mesothelioma mortality in Great Britain from 2002 to 2050. *Br J Cancer* 2005, 92:587-593.
7. La Vecchia C, Decarli A, Peto J, Levi F, Tomei F, Negri E. An age, period and cohort analysis of pleural cancer mortality in Europe. *Eur J Cancer Prev* 2000; 9: 179-184
8. Banaei A, Auvert B, Goldberg M, Gueguen A, Luce D, Goldberg S. Future trends in mortality of French men from mesothelioma. *Occup Environ Med* 2000; 57: 488-494
9. Marinaccio A, Montanaro F, Mastrantonio M, Uccelli R, Altavista P, Nesti M, Costantini AS, Gorini G. Predictions of mortality from pleural mesothelioma in Italy: a model based on asbestos consumption figures supports results from ageperiod-cohort models. *Int J Cancer* 2005; 115: 142-147
10. Acherman YI, Welch LS, Bromley CM, Sugarbaker PH. Clinical presentation of peritoneal mesothelioma. *Tumori* 2003; 89: 269-273
11. Munkholm-Larsen S, Cao CQ, Yan TD. Malignant peritoneal mesothelioma. *World J Gastrointest Surg* 2009 November 30; 1(1): 38-48.
12. Mitsuka Y, Yamazaki S, Miyakuni T, Iwama A, Funada T, Watanabe Y, Kaiga T, Okada S, Kochi M, Takayama T. Malignant Peritoneal Mesothelioma Mimicking Ischemic Colitis. *Case Rep Gastroenterol* 2010;4:238–242

Vascular Ligatures in Obstetrical Pathologies

Rares Gherai¹, Petru Chitulea²

¹ University of Oradea, Faculty of Medicine and Pharmacy, Oradea, Romania

² Department of Obstetrics and Gynaecology, University of Oradea, Faculty of Medicine and Pharmacy, Oradea, Romania

Keywords: vascular ligatures, hypogastric artery ligation, Tsurulnikov triple ligation, stepwise sequential ligation

Postpartum haemorrhage is the major cause of maternal death worldwide and therefore obstetricians have tried to find the best method of treatment. Besides drug preparations designed to increase uterine tone, there is no consensus regarding the treatment of severe postpartum haemorrhage. Many clinicians have imagined and put into practice different techniques, conservative or radical, from arterial embolization, intrauterine balloon tamponade, balloon occlusion of the hypogastric artery (more recently), to vascular ligatures as Tsurulnikov Triple Ligation, Stepwise sequential ligation, hypogastric artery ligation or even techniques of uterine compression, B-Linch plication. Selection and achieving of a technique depends on several factors including: vaginal or caesarean delivery, location and severity of postpartum haemorrhage, hospital technical equipment but perhaps most importantly, the experience of the obstetrician [5,6,9].

Although no technique has proved his efficiency in proportion of one hundred percent, and therefore there is no generally accepted consensus, there are a few situations where a certain technique may be preferred. For example it is more logical to try less invasive and conservative methods in the treatment of postpartum haemorrhage after vaginal delivery or after delivery by caesarean section without hemoperitoneum like balloon tamponade, arterial embolization (where we have interventional radiology and the patient's status allows). As well, it is obvious that we will choose for conservative or radical intraoperative surgical techniques in the presence of hemoperitoneum, retroperitoneal hematoma, uterine ruptures and others.

In our opinion the most efficient methods of treatment of severe postpartum haemorrhages are the intraoperative vascular ligations techniques. When the obstetrical pathology is not associated with hysterectomy of necessity, vascular ligatures not only proved his efficiency in the management of uterine bleeding but were also reported in the literature many pregnancies obtained after their use.

Bilateral ligation of hypogastric arteries

Although initially hypogastric artery ligation was described by Howard Kelly, before 1900's, used in the treatment of intraoperative bleeding from cervical cancer, only in 1960's were published the first cases with bilateral ligation of the hypogastric arteries in conservative treatment of severe postpartum haemorrhage [6,7].

The technique used in our clinic is the slightly modified *Te Linde* technique.

The first moment is opening the obturator fossa starting from the broad ligament, after sectioning the round ligament and the incision of the posterior sheath of the broad ligament, obliquely, in cranial sense. The peritoneal breach thus created is enlarged through digital traction, in cranio-caudal sense, to a distance of 2-3 cm cranially from the bifurcation of the common iliac artery.

After its identification, the cellular retroperitoneal tissue is dissected, identifying the bifurcation, and the external iliac artery, which is easy to isolate. From the bifurcation of the common iliac artery the sectioned pelvic peritoneum is pulled, in medial sense, and we dissect the pelvic ureter, which is intimately adherent to it.

The next moment is represented by the identification, first by palpation, of the hypogastric artery, which we feel pulsating under the exploring finger, followed by its dissection, with the dissection scissors, on a tract of 3-4 cm from the bifurcation. After isolating the hypogastric artery, we dissect its adventitia, in such a way as to make a tunnel inside of it, in order to better isolate it from the hypogastric vein, which is subjacent, and which is intimately adherent to the adventitia of the artery.

In this moment we apply a wide Pean forceps, on the artery, about 2-3 cm from the bifurcation, with which we gently pull the artery, moving it away from the vein, in such a way as to be able to achieve, through dissection with a fine dissection forceps in 'L', the intra-adventitial tunneling of the space between the artery and the vein. This is the most critical moment of the procedure, the risk of injuring the hypogastric vein being always present.

After the dissection forceps has passed through the tunnel made between the artery and the vein, its tip becoming visible, a thick (lest it should cut the artery) non-resorbable catgut is placed between its branches, which, by the retraction of the forceps, is passed under the artery and is tied.(Fig.1,2)

The first and most severe complication is represented by the injuring of the hypogastric vein, which is considered, in specialty literature, as being a lethal intra-operative accident. Due to the thin and friable walls of the vein, the attempts of ligation are doomed to fail because the ligation stitch cuts the vein, and its position, in the profoundness of the obturator fossa, makes access to it very difficult. In fact, massive hemorrhage, consecutive to the lesion to the vein, prevents the visualization of the lesion, and on the other hand gives little time for the surgeon's hemostasis attempts. Other possible complications are the pelvic ureter lesions, either direct (sectioning, ligation), or indirect (by catching the ureter in the cicatricial or adherential process,) and lesions of the obturator nerve, also direct or indirect, similarly with those of the ureter.[7,8,

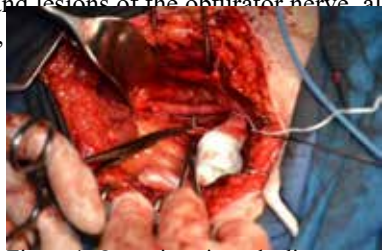

Figure 1. Operative view: the ligature must be placed about 2 cm below the bifurcation using a right angle dissector

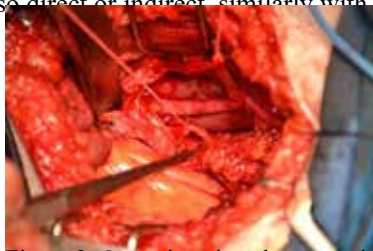

Figure 2. Operative view: hypogastric artery ligation

Bilateral uterine artery ligation

This is also an old technique, the first cases of bilateral artery ligation were published by Waters in 1952 and O’Leary in 1966 [1,2].

The technique requires an abdominal approach for which caesarean incision is adequate. The peritoneum should be opened laterally to allow identification of the right and left uterine artery pedicles. The vesic-uterine peritoneum should be reflected and division of the round ligaments may or may not be necessary to expose the pedicles. The uterus is exteriorized and pulled upwards: this tension allows identification of the vessels serving the lower segment and placement of the ligature at a safe distance from the ureters. An absorbable suture which includes the myometrium is placed 2 cm below the usual line of hysterotomy for caesarean section. This mass ligature includes the ascending branch of uterine artery without the needed to isolate it from myometrium. An identical ligation is then performed on the opposite side. This ligation technique has also been described using the vaginal route, but is seems more dangerous.[3] Generally t must be careful in choosing the place of the suture. Pl eral risk.



Figure. 3 Bilateral uterine artery ligation

Tsirulnikov triple ligation

In 1979, Tsirulnikov describes a technique developed from O’Leary technique, completing it with ligation of utero-ovarian arteries and round ligament arteries.[4] After ligation-division of the round ligament with its pedicle artery, and opening of the vesico-uterine peritoneum, the ascending branch of the uterine artery is ligated using the technique described by O’Leary. The utero-ovarian ligament is then ligated. A contralateral triple ligation is then performed. [Morel]

Stepwise sequential ligation

Stepwise sequential ligation it was imagined and described in 1994 by AbdRabbo and it involves, in principle, a uterine devascularisation in progressive steps. This technique starts with the ligation of the ovarian artery and vein, followed by the ligation of the uterine artery and vein, and finally the ligation of the descending uterine and vaginal arteries.

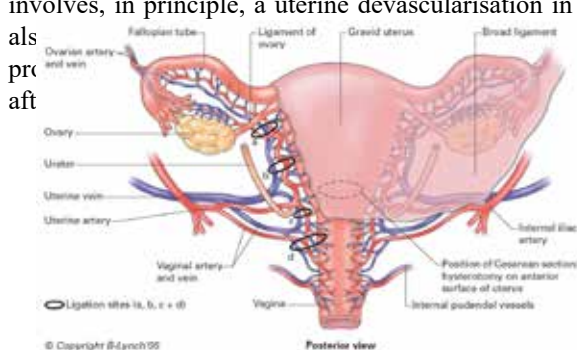


Figure 1. Placement of ligatures in the process of stepwise devascularization, including ligation of the descending uterine and vaginal arteries.

The choice of vascular ligation depends largely on personal experience of the obstetrician. For example, bilateral ligation of hypogastric artery requires a high learning curve, and because of intraoperative risks, it is not recommended to be performed by less experienced obstetricians. If the technique is applied correctly we can say that it must not present in the short term or long term comorbidities. Used correctly and on time, hypogastric artery ligation it is rescuing lives and its learning it should be mandatory in the residency preparation program.

Although if the literatures does not recommend combinations of these types of vascular ligatures, even if these techniques have been studied and published separately and not proved their efficiency in all cases, sometimes are needed.

Bibliography:

- [1] Waters EG. Surgical management of postpartum hemorrhage with particular reference to ligation of uterine arteries. A, J Obstet Gynecol 1952;64:1143-8
- [2] O'Leary JL, O'Leary JA. Uterine artery ligation in the control of intractable postpartum hemorrhage. Am J Obstet Gynecol 1966;94:920-4
- [3] Hebisch G, Huch A. Vaginal uterine artery ligation avoids high blood loss and puerperal hysterectomy in postpartum haemorrhage. Obstet Gynecol 2002;100:574-8
- [4] Tsurulnikov MS. Ligation of the uterine vessels during obstetrical haemorrhage. Immediate and long-term results. J Gynecol Obstet Biol Reprod 1979;8:751-3
- [5] Sarbu P, Pandele A, Chiricuta I, Setlacec D, Chirurgie ginecologica – vol I, II, ed. Med. Bucuresti 1982
- [6] Sciara JJ, Surgery of Sterility, Obstetrics and Gynaecology, Philadelphia; 1985
- [7] Max Thorek, Modern Surgical Technique, Copyright 1949 by J.B. Lippincott Company

- [8] Te Linde's Operative Gynecology by John A. Rock & John D. Thompson, Lippincott-Raven Publishers
[9] Munteanu I, Chirurgia endoscopica in ginecologie, Editura Academiei Romane, Bucuresti; 2008
[10] C. B-Lynch et al, Internal Iliac (Hypogastric) Artery Ligation, www.glowm.com/pdf/PPH_2nd_edn_Chap-52.pdf

Neoadjuvant chemotherapy for advanced ovarian cancer- single center results

Slobodan Maricic^{1,2}, Aljosa Mandic^{1,2}, Jelka Rajovic¹, Marina Popovic¹, Ninoslav Dejanovic¹

¹Gynecology Department, Oncology Institute of Vojvodina, Serbia

²University of Novi Sad, Medical faculty, Serbia

The gold standard in the primary treatment of the advanced stage ovarian cancer is primary debulking surgery (PS), followed by platinum-based adjuvant chemotherapy. The degree of tumor resection (optimal vs. suboptimal cytoreduction) is a major prognostic factor for survival. Therefore, achieving optimal cytoreduction of tumor tissue is imperative of advanced ovarian cancer surgery.

Neoadjuvant chemotherapy (NACT) is an alternative treatment option for advanced epithelial ovarian cancer which consists of usually 3-4 cycles of platinum-based chemotherapy, followed by interval debulking surgery (IDS) and adjuvant chemotherapy. It is meant to decrease the tumor volume making optimal cytoreduction more achievable and to decrease disease burden in patients with a poor general condition at the time of diagnosis in order to make them more fit for surgery.

From 2013. to 2016. we treated 30 ovarian cancer patients with NACT followed by IDS in our center. Patients were diagnosed in FIGO stage IV in 23,3% and in FIGO stage IIIc in 70%. Patients received 3-4 cycles of paclitaxel +carboplatin regimen (70%) or single carboplatin (10%) prior surgery. We performed 76,7% of optimal debulking surgery (residual tumor <1cm) after NACT, which is comparable with results of randomised trials.

NACT+IDS did not show the significant increase in PFS or OS compared with standard treatment in randomised trials, in spite of notably better percentage of optimal debulking achieved with NACT+IDS. Even though NACT+IDS did not prove better survival rate, increase of optimal debulking surgery can also be important.

Keywords: neoadjuvant chemotherapy, ovarian cancer.

Highschool female student's knowledge about HPV infection at University of Novi Sad **Mladenović Segedi Lj^{1,2}, Ugarković J¹**

¹ Clinic of Gynaecology and Obstetrics, Clinical Center of Vojvodina, Serbia

² Faculty of Medicine, University of Novi Sad, Serbia

Introduction: HPV infection is the most common STD of our time. The infection can be asymptomatic or manifest. High-risk types of HPV can cause cervical cancer.

The Aim: To examine female highschool student's knowledge about HPV infection.

Material and Methods: Research was conducted by questionnaire from June until September 2016 at University of Novi Sad.

Results: We examined 216 students at average 21.7 years. Our sample were students from: Medical (27.8%), Agricultural (24.1%), Social sciences (16.7%) and Technical faculty (13%). Other faculties were 18.4% of sample. Seven of ten (65%) is sexually active from average 17.9 years. All respondents heard about PAP smear, while 65% defined it correctly. HPV is defined as STD by 76% of students. Students recognize most important risk factors for HPV infection as follows: number of sexual partners (61.1%), young age (40.3%). Students know HPV infection causes genital warts (63.0%), and cervical cancer (68.5%). More than a half (59.3%) consider HPV infection as asymptomatic, 37.0% know it can be cured. Only 55.6% students heard about HPV vaccine. Every second girl (46.3%) would get vaccine, 25.9% would not. More than a half students consider their knowledge about HPV insufficient, and 92.6% of them are motivated to take up lectures about HPV infection.

Conclusion: There is a serious need for education about reproductive health for young people, about STDs, and HPV infection as main cervical cancer risk factor.

Keywords: Cervical cancer, Reproductive health, STD, HPV vaccine, Preventio.

